

डॉ० जी० एन० सिंह

Dr. G.N. Singh
CONSULTANT PHYSICIAN

MBBS (Patna); M.D. (Med) B.H.U.
Ex-S.R.F., Ex.P.D.F. (CSIR, Delhi)
Ex. Asst., Prof., Medicine.
Patliputra Medical College, Dhanbad



घनवंशीर क्लिनिक MIG-40A,
हाऊसिंग कॉलोनी धनबाद (सम्राट रोड)

समय 8-11 am } प्रति दिन
12-3 pm }
5pm - 7 pm }
Sunday - 7 am - 12 noon

मिलने का स्थान:.....

समय:

Ph. No. - 6201996624, 9006731
No Home Visi

Name: Sulshan / Khatun

18 kg

Date: 27/3

Age: (yrs) Sex: M/F

(B+Ve)

Severe Anaemia

Hepatosplenomegaly

Pit. Trislae
CBC - Hb - 15%
TC - 35100
Apl. nucleated likely blast - 33%
bone marrow

1. Arrange BT.

AFT - (N)

2. Hospital admission

LFT - (N)

3. 8y' Mono cell (3000)

X-rays chest: (N)

total iv on

USG abd

multiple enlarged conglomerated para aortic and hilar lymph nodes

28/3/24

27/3

Leucocytosis, atypical

Nucleolated mononuclear cells

(likely blast) - 33%

Severe Anaemia

Para aortic and mesenteric lymph adenopathy

Arrange BT

8y' Mono cell (3000)

total iv on

Ac. Leukemia

29/3/24

Total 2ml

Needs BT followed by

bone marrow Exam + FCM

Refd to RINTS

Panel: (paediatric diff need full)

नोट : रिपोर्ट दिखाने का समय दिन में 2-3 बजे तक, No Home Visit

X-RAY & SCAN CENTRE

Near Pandit Clinic, Middle School Road, Baran,
Dhanbad-826004, Ph: (0326) 2206677
Mob: 8404966677, 7004191230, E-mail: xrayandscan@yahoo.in

28.3.2024

NAME : GULSHAN KHATOON 7/F

REF : DR. G.N.SINGH MD

X-RAY NO : (498)

CHEST P.A.VIEW:

The lungs fields are clear.
Trachea is central.
Cardiac shadow is normal.
Hila and mediastinum are unremarkable.
Costophrenic angles are acute and sharp.
Bony cage is normal.



Dr. (Mrs.) S. Vishwakarma
M.B.B.S, D.G.O.

MULTISLICE CT-SCAN • DIGITAL X-RAY • ULTRASOUND • COLOUR DOPPLER • ECHOCARDIOGRAPHY • PAT

• This is not a final diagnosis. • Diagnosis has to be made by clinical correlation & related Pathological investigations. • Typing mistake should be corrected.
• Clinical correlation is advised for further management. • The firm not the report is valid for medico legal cases as patient identity is not known.

M.B.B.S, D.G.O.

MULTISLICE CT-SCAN • DIGITAL X-RAY • ULTRASOUND • COLOUR DOPPLER • ECHOCARDIOGRA

• This is not a final diagnosis. • Diagnosis has to be made by clinical correlation & related Pathological investigations. • Typing mistake should be corrected.
• Clinical correlation is advised for further management. • The firm not the report is valid for medico legal cases as patient identity is not known.

राजेन्द्र अग्रवाल

Dr. M M BANDOPADHYAY

SP-1011 - 9717936844 ext. 88144



राजेन्द्र अग्रवाल

डा. बी. आर. अम्बेडकर संस्थान रोटरी कैंसर अस्पताल
Dr. B.R. Ambedkar Institute Rotary Cancer Hospital
अ.भा.आ.स. अस्पताल/A.I.I.M.S. HOSPITAL
राजिस्टर सेमी रिपॉर्त/Out Patient Department
अस्पताल के अन्दर धूम्रपान करना है/SMOKING PROHIBITED IN HOSPITAL PREMISES

रिपोर्ट/Unit

DR 113/BANDP

IRCH No.

रिपोर्ट/राजिस्टर नं./O.P.D. Regn. No.

107425

रिपोर्ट/Dept.

MO

नाम/Name

GULSHAN

रिपोर्ट/पैर/मैल/हैंड/फुट
F / S / W / H / I / D of

लिंग
Sex

उम्र
Age

रिपोर्ट तिथि/Date of

F

6yrs

रिपोर्ट/Diagnosis

Acute leuk. Evaluation.

रिपोर्ट/Date

उपचार/Treatment

3-4-24

ADW

1. T. Allopurinol 100mg (1/2) TDS
2. K-blind serum (1/2) BD
3. plenty of oral fluids.
4. To come for registration — 4/4/23

PB-Flow sent for Peds Em.



GULSHAN
Resident (O)

अंगदान-जीवन का बहुमूल्य उपहार/ORGAN DONATION PLEASE GIFT O
O.R.B.O., AIIMS, 26588360, 26593444, www.orbo.org Helpline - 1060 (24
घण्टे) से आने वाले योगियों के लिए धर्मशाला की सुविधा उपलब्ध है/Dharamshala facility is available

BSM

CLINILAB

Diagnostic & Imaging Centre Pvt. Ltd
RAYABAZAR, DHANBAD

Ph: (0326) 2304803, 2302719

DR. S BANERJEE

MBBS(Cal), DMD(Cal), DNB(I)
Ex-Senior Resident
Calcutta National Medical college &
Chittaranjan Hospital, Kolkata

DR. (Prof) J SENGUPTA

MBBS(Cal), MD(Cal) Path & Bact.
Consultant : Histopathology &
Cytopathology
Ex-Professor Pathology, R G Kar
Med. College & National Med.
College, Kolkata

DR. M M BANDOPADHYAY

MBBS(Cal) Gold Medalist,
DCP(Cal) Gold Medalist, MCCP, MIAC,
FRSTM&H(UK)
Ex-Pathologist, Drs. Tribedi & Roy, Kolkata
Ex-Pathologist : Inst. of Child Health, Kolkata
Ex-Senior Pathologist & Tutor,
CENTRAL HOSPITAL, DHANBAD
LIFE MEMBER

-Indian Association of Pathologists &
Microbiologists
-Indian Academy of Cytologists
-Indian Association of Medical Microbiologists



ENROLLED WITH EXTERNAL QUALITY ASSURANCE SERVICES - (EQAS) BIORAD-USA (L.N : 5779)

SULSHAN KHATOON

DATE : 27.03.2024
ID NO. GN-15

DR. G N SINGH,

COMPLETE HAEMOGRAM (CBC/GPB) WITH ESR & RETICULOCYTES*

*BY AUTOMATED "5"-PARTS HAEMATOTOLOGY ANALYSER

HEMOGLOBIN : 2.2 G/dl 15% (M : 13-18/F : 12-16)
Children : 11-14)

First hour) : 140 mm (M : <30/F : <35)

LEUCOCYTES : 35,100/cmm (4,000 - 11,000/cmm)

CENTRAL LEUCOCYTES :

Neutrophils	: 20%	(40% - 75%: Absolute value : 2,500 - 7500/cmm)
Lymphocytes	: 43%	(20% - 50%: Absolute value : 1,500 - 3,500/cmm)
Monocytes	: 02%	(2% - 10%: Absolute value : 200 - 800/cmm)
Eosinophils	: 02%	(1% - 7%: Absolute value : 40 - 440/cmm)
Basophils	: 00%	(<2%: - Absolute value : 0 - 100/cmm.

PERIPHERAL LEUCOCYTES :

Normal nucleated : 33%
Abnormal nucleated :
Nucleated - likely Blasts

PERIPHERAL BLOOD FILM :

Cells :
Predominantly normochromic & normocytic

Platelets : -Diminished.
-Few megathrombocytes seen.

REMARKS :

Abnormalities : None found in these smears

Coagulating time (Duke's) :
Coagulating time (Wright's) :

Normal : 1 - 3 mins/CT : Normal : 3 - 5 mins.)

Abnormalities in brackets indicate "Reference range"

Total RBC : 0.80 millions/cmm (4.0-6.5 millions/cr
PCV : 6.5 % (M : 42% - 52%
F : 37% - 48%)

MCV : 81.1 fl (76 - 98 fl)
MCH : 27.3 pg/cell (28 - 33 pg/cell)
MCHC : 33.7 gm/dl (32 - 36 gm/dl)
RDW-CV : 13.6 % (11% - 16%)
PLATELETS : 131,000/cmm (150,000 - 450,000)
MPV : 16.0 fl (7 - 10 fl)
PDW : 18.9 % (8% - 16%)
PCT : 0.072 (0.2% - 0.5%)
RETICULOCYTES : 3.8% (0.5% - 2.5%)

REMARKS :

*Small-to-medium sized blasts, 1-2 inconspicuous
coarse chromatin, scanty cytoplasm, no Auer granules
L₁ & M₁ blasts are often indistinguishable by
Romanowsky's staining alone.

- Suggested :
- Clinical correlation.
 - Special staining.
 - Immunophenotyping
 - FCM
 - Bone marrow study.
 - Molecular Genetic testing.
 - Cytogenetic studies for further characterization.

-Please correlate clinically & by other relevant parameters

SHOBHA KUMARI

MS, MD (PATHOLOGY), RIMS

DR. M M BANDOPADHYAY

MBBS(Cal) Gold Medalist, DCP(Cal),
Life member, Academy of Medical Specialties

DR. S BANERJEE
 MBBS(Col), DVO(Col), DNB(U)
 Ex-Senior Resident
 Calcutta National Medical College &
 Chittaranjan Hospital, Kolkata

DR. (Prof) J SENOUPTA
 MBBS(Col), MD(Col), Path & Bact.
 Consultant : Histopathology &
 Cytopathology
 Ex-Professor/Pathology, R.G Kar
 Med. College & National Med.
 College, Kolkata

DR. M M BANDOPADHYAY
 MBBS(Col) Gold Medalist, WCCP, MAJG,
 DCP(Col) Gold Medalist, FRCP(M), UK
 FRCP(M), UK
 Ex-Pathologist, Drs. Tribedi & Roy, Kolkata
 Ex-Pathologist, Inst. of Child Health, Kolkata
 Ex-Senior Pathologist & Tutor,
 CENTRAL HOSPITAL, DHANBAD
LIFE MEMBER
 -Indian Association of Pathologists &
 Microbiologists
 -Indian Academy of Cytopathologists
 -Indian Association of Medical Microbiologists

ED WITH EXTERNAL QUALITY ASSURANCE SERVICES - (EQAS) BIORAD -USA (L.N : 5779)

REFD. BY DR. G.N SINGH, MID
 DATE : 27-03-2024

CLINICAL CHEMISTRY
 "BY AUTOANALYSER -BS-380"

TEST	RESULT	**NORMAL RANGE.
21 mg/dl	15 - 40 mg/dl	
9.8 mg/dl	8 - 20 mg/dl	
0.8 mg/dl	0.7 - 1.4 mg/dl	
3.2 mg/dl	2 - 7 mg/dl	
141 mEq/L	135 - 150 mEq/L (mMol/L)	
3.7 mEq/L	3.5 - 5.5 mEq/L (mMol/L)	

DOM ACCESS AUTOANALYSER - BS-380
(HEPATIC PROFILE) (LIVER FUNCTION TESTS)
 By : Autoanalyser - Flexor
 QC checked by : Bio-Rad controls.

TEST	RESULT	*REFERENCE RANGE
0.6 mg/dl	Low normal : 0.2 mg/dl High normal : 1.0 mg/dl	
0.2 mg/dl	0.1 - 0.3 mg/dl	
0.4 mg/dl	0.2 - 0.7 mg/dl	
25 U/L	5 - 45 U/L	
128 U/L	37 - 150 U/L (> 19 Yrs.) 37 - 260 U/L (16 - 19 Yrs.) 0 - 735 U/L (12 - 15 Yrs.) 0 - 615 U/L (0 - 12 Yrs.)	
7.8 gm/dl	5.5 - 8.0 gm/dl	
4.0 gm/dl	3.5 - 5.5 gm/dl	
3.8 gm/dl	2.0 - 3.5 gm/dl	

X-RAY & SCAN CENTRE

Near Pandit Clinic, Middle School Road, Bartand,
Dhanbad-826004, Mob.: 8404966677, 7004191230
E-mail: xrayandscan@yahoo.in

NAME: GULSHAN KHATOON	7/F	DATE: 28.3.2024
REF: DR. G.N.SINGH	MD	REG: USD-6066

REPORT ON U.S.G. EXAMINATION OF: WHOLE ABDOMEN:

LIVER:

Both lobe of liver shows normal echotexture.
Right lobe of liver measure about 12.34 cm.
No solid or cystic mass lesion are seen in the hepatic area. Extra and intra hepatic biliary radicals are not prominent. Portal vein is normal.

GALL BLADDER:

The gall bladder is normal in shape and size.
No evidence of G.B. calculi or mass lesion are seen.
Common bile duct shows normal caliber & measure 0.25 cm.

PANCREAS:

The pancreas shows normal echotexture.
No pancreatic lesions are noted.

SPLEEN:

The spleen is normal in shape and size.
No focal mass lesion is noted. Echopattern is normal. Spleen measures about 9.51 cm.

KIDNEYS:

Renal configurations are normal.
Cortico medullary demarcation is distinct.
Cortical thickness and echotexture are normal.
Renal sinuses are normal.
Right kidney measure about 7.92/3.36 cm.
Left kidney measure about 8.34/3.34 cm.

URINARY BLADDER:

The outline of the urinary bladder is normal.
No vesicle calculi or mass shadow are seen.

LOWER ABDOMEN:

Uterus and ovaries are pre-pubertal.

OTHERS:

*Mesenteric is thickened and shows enlarged lymph nodes.
Multiple enlarged conglomerate para-aortic & iliac lymph nodes are also seen. Largest measure about 1.91/0.70 cm.*

IMPRESSION: LYMPHADENITIS WITH THICKENED MESENTERY

(Please correlate clinico-pathologically)

NAMIDHARI HOSPITAL & RESEARCH CENTRE

NAYA BAZAR, DHANBAD, Ph. : 0326- 2307629

Condition: This provisional Prescription/operation/therapy/interference has been advised on the basis of SUPPLIED CONSENT of the patient and his/her guardian and is subject to further guidance from senior specialised centre.

- SURGERY & LAPAROSCOPIC
- Dr. Prof. Jyotsna Singh
M.S., F.I.C.S.
- Dr. C.D. Ram
M.S., M.D.
- Dr. Sunil K. Nayak
M.B.B.S., M.S.
- Dr. Tejas Kumar Rajak
M.B.B.S., M.S. (General Surgery)
- MEDICINE
- Dr. Prof. S.K. Sinha
M.B.B.S., M.D.
- Dr. Prof. U.K. Ojha
M.B.B.S., M.D.
- Dr. Alokh Kumar
M.B.B.S., M.D.
- ORTHOPAEDICS
- Dr. Prof. D.P. Bhushan
M.B.B.S., M.S.
- Dr. Rajesh Kumar
M.B.B.S., M.S. (Ortho)
- GYNAECOLOGY
- Dr. Kalpana Sinha
M.B.B.S., D.O.O.
- Dr. Shabana Ahmed
M.B.B.S.
- PEDIATRICS
- Dr. Neelshah Alam
M.B.B.S., DCH, PGPN (USA)
- ENT - Dr. Sujeeet Kumar
M.B.B.S., M.S.
- UROLOGY
- Dr. Rohit Kumar
M.B.B.S., DNB
- ANAESTHESIA
- Dr. B.K. Singh
- Dr. A. Priya
M.B.B.S., DA
- Dr. Piyush K. Sengupta
M.B.B.S., MD
- Dr. Shadab Ashfi
M.B.B.S., MD
- RESIDENT DOCTOR
- Dr. Amir Parwez
MD
- Dr. R. I. Singh
M.B.B.S.
- Dr. I. K. Singh
M.B.B.S.



Doctor _____

NOT FOR MEDICO LEGAL USE



Date _____

26/01/20

GURSHAN BHARDWAJ H 244

Hjk

Altohan

At Dr. Aswathul Sultan (11)

① Gas P-250 (10) ②

③ Dr. Sunil Nayak (11) Suptoy

④ Dr. Anurag (1) Suptoy

⑤ Dr. R.I. Singh (1) Suptoy

रहे रहित मुस्कान
A Painless Smile

Registration. No : OPD24/000746	Date : 24/01/2024	Gen
Patient Name : GULSHAN KHATUN	Age : 7 Years	Gen
Consultant : DR. J.P.N. BARNWAL M.B.B.S. (Hons.) M.D., DCH Ex. Professor & HOD of Pediatrics PMCH Patna	UHD : 240114391	
Address : KHARGU	Type : GENERAL	

Pulse: 124/min

PO2: 99.1.

temperature: 100.8°

Weight: 18.1 kg

few for mo
 High culture

High culture

low S, low

low S, low

CBC

Hb 3.1 g/dl
 THT 15330

Widal

N B.?

normal

SK 22

Xin

low S, low

low S, low

low S, low

low S, low

low S, low

low S, low

low S, low

low S, low

low S, low

low S, low

low S, low

low S, low

low S, low

low S, low

low S, low

low S, low

NAMDHARI LAB

Department of Pathology

Everest Building, Naya Bazar, Dhanbad (Jharkhand)

Name: GULSHAN KHATOON

Collection on: 25.01.

Dr. M.O. NAMDHARI HOSPITAL & RESEARCH CENTRE

bin : 2.9 R/dl (M.13-18/F 12-16 Children 11-14)

erythrocytes	12800	(4000-10000/Cumm)
total Leucocytes		(Normal Range)
Neutrophils	80	(40%-75%)
Lymphocytes	16	(20%-50%)
Monocytes	03	(1%-5%)
Eosinophils	01	(1%-7%)
Basophils	00	(<2%)

Count : 0.99 (4.0-6.5)

Millions/Cumm

platelet count : 90000 Cumm(1,54,000-4,50,000)

MCV	96.7	(80-100)
RDW	57.5	(27-34)
Hb	59.4	gm/dl (32.0-36.0)
Hct	28.5	% (11-16)
PLT	17.4	F1 (6.5-12)
MPV	---	% (8%-16%)
PDW	0.098	% (0.2%-0.5%)
CRP	140	mm1sthr

Microcytic hypochromic with mild anisocytosis
Leukocytosis with neutrophilia.
Thrombocytopenia.
Not seen.

Random Hemoglobin : 106.4 mg/dl

Random Hemoglobin A1c : 28.6 mg/dl

Random Hemoglobin A1c : 0.81 mg/dl

Random Hemoglobin A1c : 4 mg/dl

Random Hemoglobin A1c : 1.2 mg/dl

JAY PRAKASH HOSPITAL, KODERMA

(A unit of Jay Prakash Healthcare Pvt. Ltd.)

Chitragupt Nagar, Subhash Chawk, Ranchi- Patna Road, Jhumri Telaiya, Koderma, Jharkhand-825409

Results

Run Date 01/24/2024 10:15:12 AM

Operator JPH

Last Name

Sample ID AUTO_SID0002

First Name GULSHAN KHATUN

Department

Gender Female

Age 7 Y

Physician DR.J.P.N.BARNWAL

Patient ID 700

Type Child4

Date of birth

Sample comments

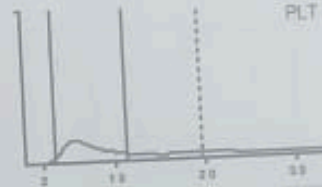
				Range
RBC	0.85	L*	10 ⁶ /μL	4.00 - 5.40
HGB	3.1	L	g/dL	11.5 - 14.5
HCT	7.5	L*	%	37.0 - 45.0
MCV	87.6	*	μm ³	77.0 - 91.0
MCH	36.3	H*	pg	24.0 - 30.0
MCHC	41.4	H*	g/dL	32.0 - 36.0
DW-CV	16.9	h*	%	11.0 - 16.0
DW-SD	55.4	H*	μm ³	37.0 - 49.0



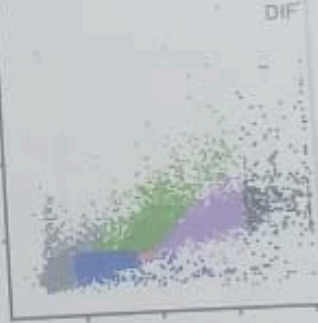
Susp. Pathologies

- Anemia
- Double RBC population ?
- Cold Agglutinins
- Thrombopenia
- PLT aggregate or NRBC ?
- Monocytosis
- Large Immature Cells

				Range
PLT	50	L*	10 ³ /μL	200 - 400
PCT	0.04	l*	%	0.15 - 0.50
MPV	8.9	*	μm ³	6.0 - 11.0
PDW	14.8	*	μm ³	11.0 - 18.0
P-LCC	15	l*	10 ³ /μL	44 - 140
P-LCR	30.8	*	%	18.0 - 50.0



				Range
WBC	10.96	*	10 ⁹ /μL	4.50 - 13.50
	#			
NEU	4.16	*	1.60 - 7.00	41.0 * 40.0 - 73.0
LYM	4.23	h*	1.00 - 3.00	41.7 * 15.0 - 45.0
MON	1.61	H*	0.20 - 0.80	15.8 h* 4.0 - 12.0
EOS	0.01	*	0.00 - 0.50	0.1 l* 0.5 - 7.0
BAS	0.15	*	0.00 - 0.15	1.4 * 0.0 - 2.0
LIC	0.80	H*	0.00 - 0.10	7.9 H* 0.0 - 1.0



Slide Review

- | | | |
|---------------------|---------------|-----------------|
| Neutrophil | Myeloblast | Anisocytosis |
| Lymphocyte | Promyelocyte | Hypochromia |
| Monocyte | Myelocyte | Polychromasia |
| Eosinophil | Metamyelocyte | Poikilocytosis |
| Basophil | Blast | Microcytosis |
| Atypical Lymphocyte | Target Cell | Macrocytosis |
| Other | Sickle Cell | Platelet Clumps |

Reviewed on _____ by _____ Signature :

Printed by : JPH

S/N 209YOXH04942

01/24/2024 10:16:28 AM

नोट : रि



डा. बी. आर. अम्बेडकर संस्थान रोटरी कैंसर अस्पताल
Dr. B.R. Ambedkar Institute Rotary Cancer Hospital
अ.भा.आ.र
बहिरंग

OPR-6

अस्पताल का अन्दर फु
DR. B.R.A. BHICHAHMS, NEW DELHI
Reg. Date: 04/03/2011
Class No. 2024/749

कक्षा/Unit Dr. 68/MDP
विभाग/Dept. MO

नाम/Name Gulshan

नाम: GULSHAN KHATUN
DOB: ABDUL QUAJUM
Phone No. 9007926456
Address: GRAM KHARGU POST CHAUDI, THANA CHALUKISHA, CHAUDI HAZARIBAGI, BHARKHANI, P.O. 825109, INDIA

Reg. No. 10142203
Date of Birth

निदान/Diagnosis: Leis: AML (Induction w.e.t 21/4/24)

दिनांक/Date	उपचार/Treatment
<u>18/4/24</u>	<p><u>advice</u></p> <p>- Tab. Magnex 1 gm IV BD } Till 18/04/24 R.No: 15</p> <p>- Tab. Amikacin 200 mg IV OD</p> <p>- syp. Lanzol JR 15 mg OD x 5d</p> <p>- T. Emetet 4 mg SOS</p> <p>- T. PCM 500 mg SOS</p> <p>- Chlorhexidine mouth wash } TDS</p> <p>- steam inhalation</p> <p>- seitz Bath</p> <p>- Plenty of fluids</p> <p>- In case of bleeding - Tab. Tranexa 250 mg stat & visit paed. emergency.</p> <p>- Inform Dr. Santosh in case of fever - 38617705.</p>

- Hup in HO-OPD on 18/04/2024 with
CRC/LFT/KFT reports.



18/4/24

D1 (E) 18/4/24
Cont Mag x 4 day (ch 21-15)
Cont Amikins x 4 day
BT - 1 D → New p.w. ward day care
CBC - 21/4
Fr on 22/4
Vanner

18/4/24
1160
12.95



डा. बी. आर. अम्बेडकर संस्थान रोटरी कैंसर अस्पताल
Dr. B.R. Ambedkar Institute Rotary Cancer Hospital
अ.भा.आ.र

OPR-6

संस्थान का चिह्न

बहिरंग
अस्पताल के अंदर से

DR. B.R. AMBEDKAR NEW DELHI
HCC No. 37227
Class: Postgraduate Medical Faculty Class
Dept: MEDICAL ONCOLOGY
General
Reg No: 0104204
Class No: 0007300
LIBB: 10742700

रूम/Unit Dr. SA/Dr DP
विभाग/Dept MO

नाम/Name

Gulshan

नाम: GULSHAN KHATUN
DOB: 19/01/1978
Phone No: 907830411
Address: GRAM BARBQ, POST CHAUDH, TEANA CHALUNDA,
DISTRICT: HAZARIBAGH, BIHAR, PIN: 823008, INDIA

Date of Birth

रोग/Diagnosis

Acute: AML (Induction w/e: 8/4/24)

दिनांक/Date

10/4/24

उपचार/Treatment

advise

- Jay Magnex 1 gm IV BD } till 10/04/24
- Jay Amikacin 200 mg IV OD } R.No: 15
- syp. Lanzol JR 15 mg OD x 5d
- T. Emeset 4 mg SOS
- T. PCM 500 mg SOS
- Chlorhexidine mouth wash } TDS
- steam inhalation
- seitz Bath
- plenty of fluids
- In case of bleeding - Tab Tranexa 250 mg stat
- R visit paed. emergency.
- Inform Dr. Santosh in case of fever - 886177052



ARK PHARMACEUTICALS
 (Pharmaceuticals & Surgical Distributors)
 S-14 GROUND & 1ST FLOOR, UPHAR CINEMA COMPLEX MKT
 GREEN PARK EXT., NEW DELHI-110016

Tel No. : 011-40743520/21/22/23/24-40566802, 41017774
 Mobile Number : 7428397365, 08800300118, 8800300119, 09310155904, 09310155905
 Website : www.arkpharma.com E-mail : arkdelhi@arkpharma.com State Code : 07
 GST No. : 07AAHF-A2350E1Z7Y
 D.L. No. : MLN-139620/21/22/23/24/25, 20, 2008, 21, 21B, 20F, 20G
 PAN No. : AAHF-A2350E
 FSSAI No. : 1317008000034
 Mode Of Transport : Blue Auto/Taxi/Center/Bus

Customer Details :- 82003
GULSHAN KHATTUN
 AINIS PRATHAM CARE FOUNDATION
 AINIS HOSPITAL
 NEW DELHI
 PIN CODE : 110029
 D.L. No. 1:
 D.L. No. 2
 Ship To :-

***** RETAIL INVOICE *****
 GST No :
 Tel No : 9607950416
 Mob. N

ORIGINAL
 Invoice No. : **BOS-24-4678**
 Invoice Date : 29/05/2024
 Challan No. :
 Challan Date :
 P-Order No. :
 P-Order Date :

SR.	PRODUCT NAME	HSN CODE	PACK	BATCH NO.	EXP. D.T.	MFG. D.T.	MRR.	SALE QTY.	DIS. QTY.	RATE	AMOUNT	DIS%	TAXABLE AMOUNT	GST%	CGST %	SGST %	IGST %
1.	SPECTRA OPTIA PLATELET PLASMA KIT	90189099	10400	2311303141	11/25	11/23	14634.00	1	--	7125.00	7125.00	0.00	7125.00	12	6.00	6.00	0
2.	ACD BAG 500ML (PB-1ACS008Y)	30049099	500ML	02K23Y6	11/25	11/23	473.00	1	--	350.00	350.00	0.00	350.00	12	6.00	6.00	0
HDPC BANK-081 83721 29/05/24 																	

No of Items : 2	Taxable Amt.	CGST%	CGST Amt	SGST%	SGST Amt	Gross Amt	7475.00	
Tot Qty : 2	0.00	14 %	0.00	14 %	0.00	Sem. Amt	0.00	
Made By : TULSI	0.00	9 %	0.00	9 %	0.00	Disc. Amt	0.00	
Print By : TULSI	7475.00	6 %	448.50	6 %	448.50	Add CGST	448.50	
	0.00	2.5 %	0.00	2.5 %	0.00	Add SGST	448.50	
	0.00	0 %	0.00	0 %	0.00	Net Amount:	8372.00	
Total :	7475.00		448.50		448.50	Less CN :	0.00	
Invoice Amount in Words (Rs.) : Eight Thousand Three Hundred Seventy Two Only							Inv. Amt. R/OFF	8372.00

BANK ACCOUNT DETAIL
ARK PHARMACEUTICALS
 BANK NAME : YES BANK LIMITED
 A/C NO. : 005583900002099
 BRANCH : GREEN PARK
 IFSC CODE : YESB0000055
 NEW DELHI-110016



Terms & Conditions :-
 All Disputes Are Subjected To Delhi Jurisdiction Only.
 Interest @18% P.a. will be charged after due date.
 Goods Once Sold Will Not Be Taken Back Or Exchange

For ARK PHARMACEUTICALS

