




दिनांक - Date

उपचार- Treatment

DOA  
 04/04/20  
 R.No 34A, 8:30am  
 h



Advice :

- NVZ Out
- flat-AC
- 10p. digitaly Prod.
- Poor glass Out
- (RE) USG - mass with calcification

- Phisical bulbi
- inferior squab
- cataractous lens

Sign

D: B/L Group E RB.

Ad

→ ref to ~~Dr. Jagdish Mehta~~ Dr. Loni Sir's opinion for starting systematic chemotherapy.

नित्र ईश्वरीय सर्वश्रेष्ठ उपहार है जिनका मनुष्य जीवन में दान करना परमश्रेष्ठ है।  
 इनकी पूर्ण रक्षा कीजिए ताकि ये आपकी रक्षा कर सकें।  
 Eyes are God's most precious gift to man kind. Take full care of them  
 So that they can take care of you.

Myom efd (2) xrd  
 (34A) (BE)  
 for emble  
 (Close) emble

Room 10

Dr. Jaganjit Singh

ब० रो० वि० कार्ड  
O.P.D. Card

डा० राजेन्द्र प्रसाद नेत्र विज्ञान केन्द्र,  
अ० भा० आयु० सं०, नई दिल्ली - ११००२९  
Dr. Rajendra Prasad Centre for Ophthalmic Sciences



ये र अमृत्यु उपहार है  
जो आप ही दे सकते हैं

अनुभाग व दिन  
Section and Day VI  
बुधवार व शनिवार  
Wednesday & Saturday

कमरा नंबर  
Cabin No.

ब० रो० वि० कार्ड

DR. RAJENDRA PRASAD CENTRE FOR OPHTHALMIC SCIENCES

डा  
अ  
Dr  
A  
यु  
L

UHID: 102609674  
Dept. No.: 20200950020370  
KRISHNA KUMAR 2Y M  
S/O: RAJENDRA PRASAD  
Date: 07/03/2020  
RPC OPD-Dr. NEIWETE  
LOMII  
Unit-VI WED, SAT  
Room No.: 32  
Address: MUZAFFARPUR, BIHAR, INDIA  
Mobile: 9089743310



अनुभाग व दिन  
Section and Day VI  
बुधवार व शनिवार  
Wednesday & Saturday

कमरा नंबर  
Cabin No. 7/3/20

न का एकक  
Anderson's Unit

आयु  
Age  
पता  
Address

Krishna Kumar

M 2y

दिनांक  
DATE

निदान  
DIAGNOSIS

उपचार Treatment

27/02/2020

C/S/B NIRC

neovascular structures

→ @ T2 heterogenous ~~mass~~ involving whole of  
rt globe. c some exudates

Cannot rule out Rb or RD - inconclusive

Date for EUA  
next week.

07 MAR 2020

2-7/9/20 Kindly provide accommodation  
in Dhansala. (RB pt)  
C/D/w  
Dr. N. Lomi  
(CONSULTANT)  
SR/UG  
RAC/AMMS

कृपया इस कार्ड को सुरक्षित रखें तथा अस्पताल में दिखाने के समय हर वक़्त साथ लायें।  
Kindly keep this Card safely and bring it on your follow-up visits.

१. धूम्रपान निषेध २. कूड़ा कर्कट केवल कूड़ेदान में ही डालें ३. थूकिये नहीं

O.P.D. Card

DR. RAJENDRA PRASAD NEETRA VIGYAN KENDRA,  
Bhadracharya Rd, New Delhi - 110002

Section and Day VI  
बुधवार व शनिवार  
Wednesday & Saturday

कमरा नंबर  
Cabin No.

अनुभाग व दिन  
Section and Day VI  
बुधवार व शनिवार  
Wednesday & Saturday

कमरा  
Cabin

R.B - 41/20

व. र. के. ति. कार्ड

DR. RAJENDRA PRASAD CENTRE FOR OPHTHALMIC SCIENCES

CHID: 105089614  
Depd No. 20200050020370  
KRISHNA KUMAR IVN  
M.O. JETAENDRA CHAUDHARY

Date: 17/02/2020  
RPC OPD-De SR/IR  
UNDER UNTIL IV R.39A  
Cabin IV SIGN: TDR  
Revis No: 39A

भाग व दिन  
Section and Day IV  
बुधवार व गुरुवार  
Wednesday & Thursday

कमरा नंबर  
Cabin No.

Address: MITRA NAGAR, BIHAR, INDIA  
Mobile: 2080 43510



एकक  
Unit

Name of the Patient	S/D/W	Sex	Age	पता Address
दिनांक DATE	निदान DIAGNOSIS	उपचार Treatment		

दिनांक DATE      निदान DIAGNOSIS

उपचार Treatment

~~10~~ whitish reflex x 3 months  
HIO swelling in (L) → gradually  
became small.

AE (R)      (L)  
leucocoria      pre phthical.

1. Anterior stromal  
USG for AE PLE (R) moderate amplitude spikes in  
vitreous cavity S/O VU/VE  
fo P/O RB (L) small disorganised globe  
? RB

कृपया इस कार्ड को सुरक्षित रखें तथा अस्पताल में दिखाने के समय हर वक्त साथ लायें।  
Kindly keep this Card safely and bring it on your follow-up visits.

- धूम्रपान निषेध
- कूड़ा कर्कट केवल कूड़ेदान में ही डालें
- थूकिये नहीं

O.P.D. Card

DR. RAJENDRA PRASAD NEETRA VIGYAN KENDRA,  
Bhadracharya Rd, New Delhi - 110002

Section and Day VI  
बुधवार व शनिवार  
Wednesday & Saturday

कमरा नंबर  
Cabin No.

अनुभाग व दिन  
Section and Day VI  
बुधवार व शनिवार  
Wednesday & Saturday

कमरा  
Cabin

R.B - 41/20

व. र. के. वि. कार्ड

DR. RAJENDRA PRASAD CENTRE FOR OPHTHALMIC SCIENCES

CHID: 105089614  
Depd No. 20200050020370  
KRISHNA KUMAR IVN  
M.O. JETAENDRA CHAUDHARY

Date: 17/02/2020  
RPC OPD-De SR/IR  
UNDER UNTIL IV R.39A  
Cabin IV SIGN: TDR  
Revis No: 39A

भाग व दिन  
Section and Day IV  
बुधवार व गुरुवार  
Wednesday & Thursday

कमरा नंबर  
Cabin No.

Address: MITRA TARPUR, BIHAR, INDIA  
Mobile: 2080 43510



एकक  
Unit

आयु पता  
Age Address

Name of the Patient

S/D/W

Sex

Age

Address

दिनांक निदान  
DATE DIAGNOSIS

उपचार Treatment

1/0 ~~red~~ whitish reflex x 3 months  
HIO swelling in (L) → gradually  
became small.

AE (R) (L)  
leucocoria pre phthical.

1/1 Anterior strom  
(12/6) USC for AE PLE (R) moderate amplitude fibres in  
vitreous cavity S/O VU/VE ?RB  
fo P/O RB (L) small disorganised  
globe

कृपया इस कार्ड को सुरक्षित रखें तथा अस्पताल में दिखाने के समय हर वक्त साथ लायें।  
Kindly keep this Card safely and bring it on your follow-up visits.

- 1. धूम्रपान निषेध 2. कूड़ा कर्कट केवल कूड़ेदान में ही डालें 3. थूकिये नहीं

ब० रो० वि० कार्ड  
O.P.D. Card



अनुभाग व दिन  
Section and Day VI कम्परा नंबर

Section and Day VI  
Wednesday & Saturday

कम्परा नंबर  
Cabin No.

ब० रो० वि० कार्ड  
O.P.D. Card



अनुभाग व दिन  
Section and Day VI  
बुधवार व शनिवार  
Wednesday & Saturday

कम्परा नंबर  
Cabin No.

डॉ० राजेन्द्र प्रसाद नेत्र विज्ञान केन्द्र,  
अ० भा० आयु० सं०, नई दिल्ली - ११००२९  
Dr. Rajendra Prasad Centre for Ophthalmic Sciences  
A.I.I.M.S., New Delhi-110029

वे अमृत कृत हैं  
जो आप को दे सकते हैं

यु एच आई डी संख्या  
UHID No. 105089674

आचार्य राधिका टंडन का एकक  
Prof. Radhika Tandon's Unit

रोगी का नाम Name of the patient	पुत्र/पुत्री/पत्नी S/D/W	लिंग Sex	आयु Age	पता Address
KRISHNA KUMAR		M	2yr	

दिनांक DATE	निदान DIAGNOSIS
----------------	--------------------

उपचार Treatment

19/2/20

QS/B Dr. Loni. in Ocular Oncology Clinic  
(Unit 6)

- Ⓡ RB on USA
- Ⓛ ptiasis bulbi

Advice →

- MRI Brain & orbit with Contrast enhanced, Fat Suppressed - Axial, Coronal, Sagittal sections with sections passing through optic nerve & pineal gland (2mm sections)

Urgent - CAN KIDS

- Date for EUA → for Staging → 21/2/20  
Come to 63<sup>rd</sup> SAM  
NPO from 2AM

कृपया इस कार्ड को सुरक्षित रखें तथा अस्पताल में दिखाने के समय हर वक्त साथ लायें।  
Kindly keep this Card safely and bring it on your follow-up visits.

१. धूम्रपान निषेध २. कूड़ा कर्कट केवल कूड़ेदान में ही डालें ३. थूकिये नहीं

ब० रो० वि० कार्ड  
O.P.D. Card

डा० राजेन्द्र प्रसाद नेत्र विज्ञान केन्द्र,  
अ० भा० आयु० सं०, नई दिल्ली - ११००२९  
Dr. Rajendra Prasad Centre for Ophthalmic Sciences  
A.I.I.M.S., New Delhi-110029



अनुभाग व दिन Section and Day	VI
बुधवार व शनिवार Wednesday & Saturday	

कमरा नंबर  
Cabin No.

यु एच आई डी संख्या  
UHID No.

105089674

आचार्य राधिका टंडन का एकक  
Prof. Radhika Tandon's Unit

रोगी का नाम Name of the patient	पुत्र/पुत्री/पत्नी S/D/W	लिंग Sex	आयु Age	पता Address
Krishna Kumar		M	3y	Ph-8089743310

दिनांक DATE	निदान DIAGNOSIS
	R/E Extraocular Retinoblastoma L/E ? Group E Retinoblastoma

27/7/20

उपचार Treatment  
wt - 13 kg.  
C/D/W Dr. Yogita (SR Unit VI).

- Adv:
- Syp. Augmentin (228mg/5ml) 2.5ml TDS x 5 days
  - Syp. PCM (250mg/5ml) 4ml BD x 3 days

- RE
- E/D HA 2/- BD
  - E/D Iolien BD 10TIM BD
  - E/D Oupol BD
  - E/D Milfox BID

- Hygiene & cleaning explained, Dressing done.

कृपया इस कार्ड को सुरक्षित रखें तथा अस्पताल में दिखाने के समय हर वक्त साथ लायें।  
Kindly keep this Card safely and bring it on your follow-up visits.

- धूम्रपान निषेध
- कूड़ा कर्कट केवल कूड़ेदान में ही डालें
- शूकिये नहीं



अ० भा० आ० सं० अस्पताल / **A.I.I.M.S. HOSPITAL**  
बहिरंग रोगी विभाग / **Out Patient Department**  
अस्पताल के अन्दर धूमपान मना है। / **SMOKING IS PROHIBITED IN HOSPITAL PREMISES**



OPR-6

एक/Unit  
विभाग/Dept  
नाम/Name

Follow Up Patient  
Dept Reg. 2020/001/0007144      General/W O  
Paediatrics/Paediatric /Unit-121      Ward/Room: 10  
नाम: सुष्मा कुमारी      Days: Wed, Sat (वृ, शनि)  
Name: Mr. KRISHNA KUMAR      Queue No.: P9  
पता: प्रियंका चौधरी      3V 4B 6D पुष्प, 9  
1/0 JYANGRA CHAUDHARY      Ph: 8089743310  
UMID: 10509674      Date: 23/12/2020

No. \_\_\_\_\_  
पता/Address \_\_\_\_\_

8089743310

निदान/Diagnosis

BLK RB      (R) CORB

दिनांक/Date

(4)

उपचार/Treatment

(L) OP BRB

13 Kg

Received 4 cycles of NACT

BMD Positive for metastatic disease

Post 3 cycles of chemo - MRI orbit + Brain =>

(NRe) => (Rt) eye mass present retrobulbar enhancing ON Hll optic canal, no Leptomeningeal enhancement  
non-operable

CSF - Acellular

plan to repeat MRI after 6 cycles

21/12/20

Hb-10.1  
PLT- 249 x 10<sup>3</sup>  
TLC- 5530  
ANC- 2470  
KES/LEP (N)

Next: Due for 5th cycle

- 1mg VCR 0.3 mg W (D1)
- 1mg CARBOPLATIN 360 mg W (D1)
- 1mg ETOPOSIDE 155 mg W (D1, P2)



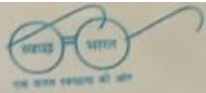CLEAN AND GREEN AIIMS / एम्स का यही संकल्प, स्वच्छता से काया कल्प  
अंगदान-जीवन का बहुमूल्य उपहार / ORGAN DONATION - A GIFT OF LIFE  
O.R.B.O., AIIMS, 26588360, 26593444, www.orbo.org Helpline - 1060 (24 hrs service)







अ० भा० आ० सं० अस्पताल / A.I.I.M.S. HOSPITAL  
बहिरंग रोगी विभाग / Out Patient Department



अस्पताल के अन्दर धूम्रपान मना है। / SMOKING IS PROHIBITED IN HOSPITAL PREMISES

OPR-6

New Patient  
Dent No: 2020/001/0007144  
Gender: M  
Date of Birth: 10/01/1981  
Name: KRISHNA KUMAR  
Address: 15/10, JALAKHIA CHAUDHARY JV BR 250 PURA  
Phone: 8089743330  
Date: 11/03/2020

व० रोगी व० पंजीकृत सं० / O.P.D. Regn. No.

लिंग Sex	आयु Age	पता / Address

निदान / Diagnosis

दिनांक / Date

15

उपचार / Treatment

Qo (L) eye small x 14s  
(R) eye whitish reflex - 4-32  
no fever  
no vomiting

(L) ear pain - on 20/2

ie - ACCELA

systemic exam - nil

EUR (9/3/20) → (R) eye - group C RB  
(L) eye - group C RB + phthor

MR (orbit + brain) septa →

(R) E → intra orbital mass seen in (R) eye globe,  
enhancement of proximal part of ON ⊕

(L) eye → phthor bulbi + intra orbital mass lesion ⊕



CLEAN AND GREEN AIIMS / एम्स का यही संकल्प, स्वच्छता से काया कल्प

अंगदान-जीवन का बहुमूल्य उपहार / ORGAN DONATION - A GIFT OF LIFE

O.R.B.O., AIIMS, 26588360, 26593444, www.orbo.org Helpline - 1060 (24 hrs service)





अ० भा० आ० सं० अस्पताल / A.I.I.M.S. HOSPITAL  
बहिरंग रोगी विभाग / Out Patient Department  
अस्पताल के अन्दर धूम्रपान मना है / SMOKING IS PROHIBITED IN HOSPITAL PREMISES



एकक/Unit

विभाग/Dept.

नाम/N

OPR-6  
Inpt No. 2020/098/0008261  
GENERAL/OP  
NAME OF PATIENT: KRISHNA  
AGE: 1yr, 6M  
SEX: (M/F)  
PH. 8089741110  
LMD: 105089674 Date: 03/03/2020

is/O.P.D. Regn. No.

पता/Address

105089674

निदान/Diagnosis

दिनांक/Date

उपचार/Treatment

Suspected case of R.B.  
↓ RPe evaluation

→ Please do early.

Adv.:

-- 4116 Bh

gentle ERM sh  
after instilling xylocaine

Bh ear discharge & pain  
recurrent x many months

-- Days

Augmentin

2.5ml

X 7 days

3/3/2020

Child un-cooperative

Bh EAC (cartilage)  
clustering (+)

-- Ciplox - D

2ld.

- w - w - w X 7 days

Thm not an as kid  
is having pain.

-- lye

Calpol

2.5ml TDS.

X 5 days.

TM attempted  
child very uncooperative

-- RA 7 days

Phazax

CLEAN AND GREEN AIIMS / एम्स का यही संकल्प, स्वच्छता से काया कल्प

अंगदान-जीवन की बहुमूल्य उपहार / ORGAN DONATION - A GIFT OF LIFE

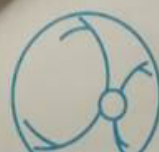D.R.B.O., AIIMS, 26588360, 26593444, www.orbo.org Helpline - 1060 (24 hrs service)

AIIMS, New Delhi - 110028

ERM on O side  
clear defect  
मेरा अस्पताल  
My Hospital  
A.I.I.M.S. Hospital  
R. Pathak



4057




fishtheye.org, Toll Free no. ...  
Please ...

MRB

- MRB

उपचार



Right Eye  
Past  
Sys

MRB ... Lower ... Outer ...

- (Unit 6)
- (R) RB on USA
- (L) pthisis bulbi

Advice ->

~~SR  
19/10/20~~

1. MRI Brain & orbit with contrast enhanced, Fat Suppressed - Axial, Coronal, Sagittal sections with sections passing through optic nerve & pineal gland (2mm sections)

Urgent - CAN KIDS

2. Date for EUA -> for Staging -> 21/2/20  
Come to 63 @ 8AM  
NPO from 2AM

कृपया इस कार्ड को सुरक्षित रखें तथा अस्पताल में दिखाने के समय हर वक्त साथ लायें।  
Kindly keep this Card safely and bring it on your follow-up visits.

- धूम्रपान निषेध
- कूड़ा कर्कट केवल कूड़ेदान में ही डालें
- थूकिये नहीं

CANKIDS...KIDSCAN  
CKID 105089674  
No. 25 Social Support Team

Eye Care System & RESEARCH CENTRE  
CLEAN AND GREEN AIIMS /

अंगदान-जीवन का बहुमूल्य उपहार / ORGAN DONATION - A GIFT OF LIFE  
O.R.B.O., AIIMS, 26588360, 26593444, www.orbo.org Helpline - 1060 (24 hrs service)



Investigations :

IOP [ ] .....mm of Hg  
[ ] .....mm of Hg  
BP .....mm of Hg

ROPAS :

SYRINGING [ ]


EYE : RE

FEUM/Cycloplegic / Auto  
Orthoptics / Color Vision / Diplopia chart (S)  
Low vision / Contact Lens  
AVF / FDT / FFA / B-scan  
YAG Laser : YLC / PI  
Retinal laser : PRP / Grid / Sectoral  
Schirmer's Test / Gonioscopy  
Lab : Gram's / CBC / BT / CT / Platelet / Sugar : F / PP / R  
OTHERS :

Free  
→ calcification  
in retina  
→ PP  
S/O Retinoblastoma

REFRACTION :

P.G. : RE :  
LE :  
Add :



2 Retinoblastoma  
~~PAIR~~ → (2) ~~eyes~~  
microphthalmos

Diagnosis : OD / OS / OU :

RECOMMENDATION / PLAN :-

Refer to mechi EYE Hospital for management

BP KITHS DHARAMI

✓

Drishiti

25 Feb 2019

Phone - Fax - Email

Krishna Chandra

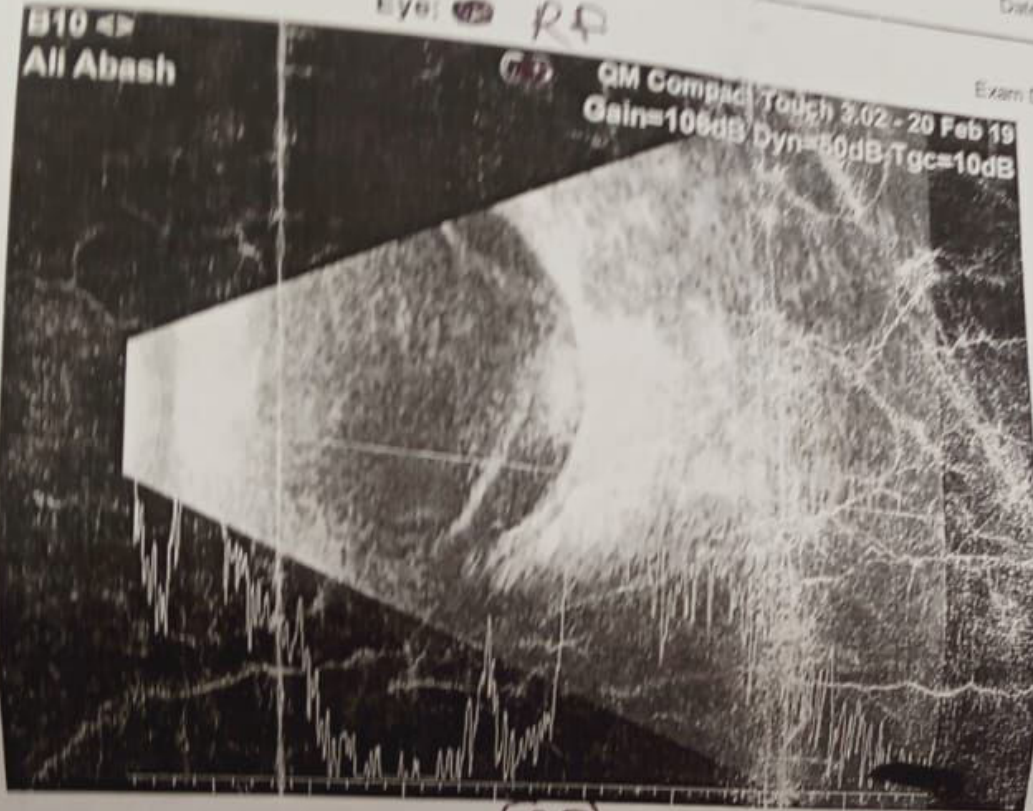
Gender

Id Number:

1828

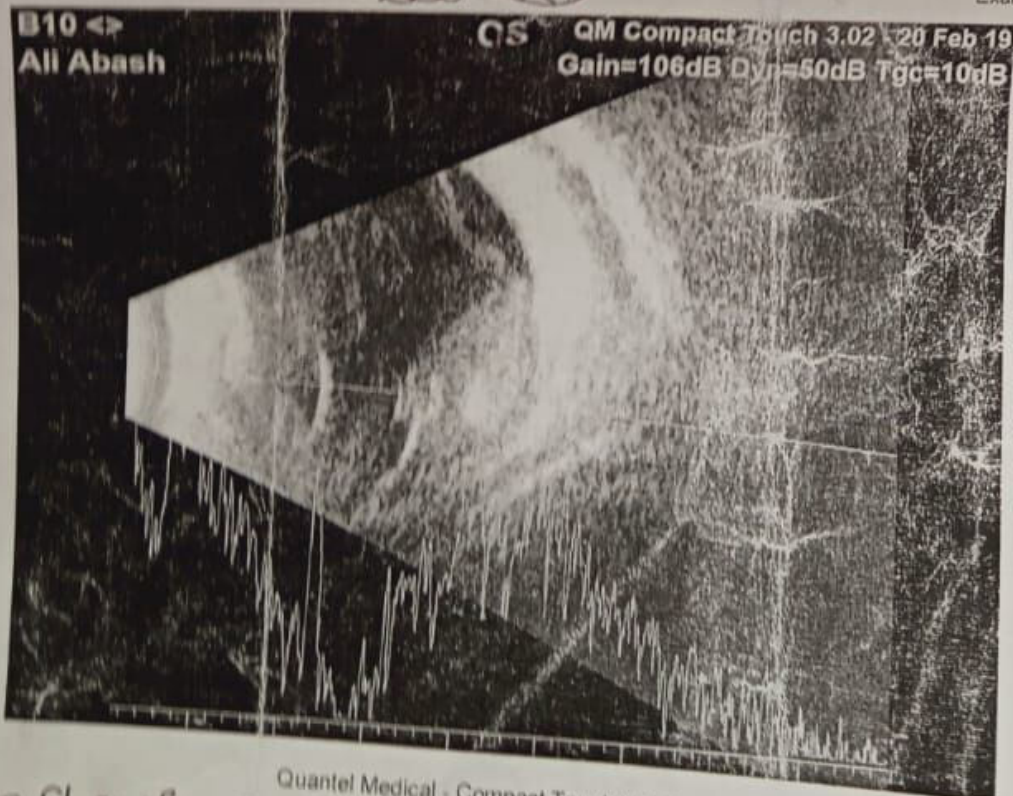
Date of birth: 01 Jan 1990

Exam Date: 20 Feb 2019



Eye: ~~OS~~ (RF)

Exam Date: 20 Feb 2019



Quantel Medical - Compact Touch V 3.02

son shows

Deme vit abn...

Next visit .....  
 Cycle no ..... Date 19/3/2020  
 Hb 10 TLC 6880 ANC 32% Platelets 3 L  
 SGOT 30 SGPT 13 S Bil 0.12 Urea 19 Creatinine 0.13

Drugs	Dose given	Day
VCR	0.3 mg iv slow push	D1 } D2 } D3 }
Carboplatin	336 mg / 200 ml NS iv 2 hr	D1 } D2 } D3 }
Etoposide	144 mg / 300 ml NS iv 3 hr	

Next visit .....

Cycle no ..... Date .....  
 Hb ..... TLC ..... ANC ..... Platelets .....  
 SGOT ..... SGPT ..... S Bil ..... Urea ..... Creatinine .....

Drugs	Dose given	Day
VCR		
Carboplatin		
Etoposide		

Next visit.....

Cycle no 10 Date 19-3-2020  
Hb 10 TLC 6880 ANC 32% Platelets 3.09 L  
SGOT 30 SGPT 13 S Bil 0.12 Urea 19.3 Creatinine 0.17

Drugs	Dose given	Day
VCR	0.3 mg iv slow pr	<u>D1</u> <i>pristhe</i>
Carboplatin	336 mg / 200 ml NS iv 1 h	<u>D1</u>
Etoposide	144 mg / 300 ml NS iv 3 h	<u>D1</u>   <u>D2</u> <i>pristhe</i>

Next visit.....

Next visit.....

Cycle no ..... Date.....  
Hb..... TLC..... ANC..... Platelets.....  
SGOT..... SGPT..... S Bil..... Urea..... Creatinine.....

Drugs	Dose given	Day
VCR		
Carboplatin		
Etoposide		

Next visit.....

कृपया इस कार्ड को सुरक्षित रखें तथा अस्पताल  
Kindly keep this Card safely and  
क्या इस कार्ड को सुरक्षित रखें तथा अस्पताल  
Kindly keep this Card safely and

Defaunite / Irregular  
cycles

KRISHNA

Cycle no ..... Date 25/11/20 + 26.11.20.  
Hb 8.1 TLC 6000 ANC ..... Platelets 13L  
SGOT ..... SGPT ..... S Bil ..... Urea ..... Creatinine .....

Drugs	Dose given	Day
VCR	0.3 mg iv	D <sub>1</sub> ✓
Carboplatin	340 mg / 100 ml NS	D <sub>1</sub> ✓
Etoposide	145 mg / 100 ml NS	D <sub>1</sub> , D <sub>2</sub> ✓
		NY Prakasham.

Next visit.....

Cycle no ..... Date 23/12/20.

Hb ..... TLC ..... ANC ..... Platelets .....  
SGOT ..... SGPT ..... S Bil ..... Urea ..... Creatinine .....

Drugs	Dose given	Day
VCR	0.3 mg iv	D <sub>1</sub> ✓
Carboplatin	360 mg / 100 ml NS	D <sub>1</sub> ✓
Etoposide	155 mg / 100 ml NS	D <sub>1</sub> , D <sub>2</sub> ✓
		23/12/20
		24/12/20



## Classification & staging

### Intraocular

Intraocular retinoblastoma is localized to the eye and may be confined to the retina or may extend to involve other structures such as the choroid, ciliary body, anterior chamber, and optic nerve head. Intraocular retinoblastoma does not extend beyond the eye into the tissues around the eye or to other parts of the body.  
(Intraocular disease (Enucleation is curative in >95% of patients with unilateral disease.)

### Extraocular

Extraocular (metastatic) retinoblastoma has extended beyond the eye. It may be confined to the tissues around the eye (orbital retinoblastoma), or it may have spread to the central nervous system, bone marrow, or lymph nodes (metastatic retinoblastoma).

## Classification of intraocular RB

### Reese-Ellsworth Classification for Intraocular Tumors

Reese and Ellsworth developed a classification system for intraocular retinoblastoma that has been shown to have prognostic significance for maintenance of sight and control of local disease at a time when surgery and external-beam radiation therapy (EBRT) were the primary treatment options.

Group I: very favorable for maintenance of sight

1. Solitary tumor, smaller than 4 disc diameters (DD), at or behind the equator.
2. Multiple tumors, none larger than 4 DD, all at or behind the equator.

Group II: favorable for maintenance of sight

1. Solitary tumor, 4 to 10 DD at or behind the equator.
2. Multiple tumors, 4 to 10 DD behind the equator.

Group III: possible for maintenance of sight

1. Any lesion anterior to the equator.
2. Solitary tumor, larger than 10 DD behind the equator.

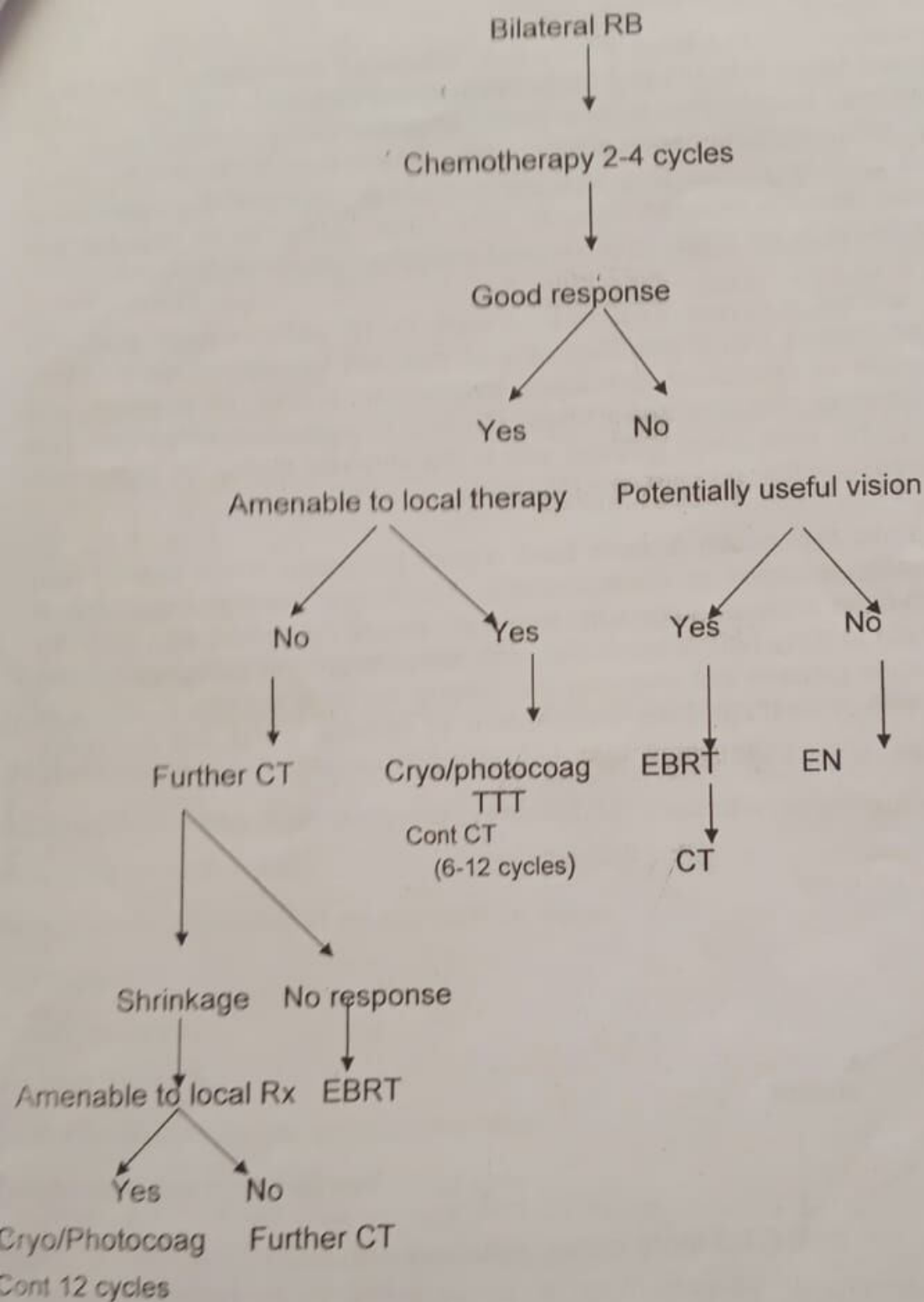
Group IV: unfavorable for maintenance of sight

1. Multiple tumors, some larger than 10 DD.
2. Any lesion extending anteriorly to the ora serrata.

Group V: very unfavorable for maintenance of sight

1. Massive tumors involving more than one half of the retina.
2. Vitreous seeding.

# Useful clinical approach to B/L RB





अ० भा० आ० सं० अस्पताल / A.I.I.M.S. HOSPITAL  
बहिरंग रोगी विभाग / Out Patient Department



अस्पताल में अन्दर घुसने पर धूम्रपान / SMOKING IS PROHIBITED IN HOSPITAL PREMISES

बहिरंग रोगी विभाग

रोगी / Unit  
विभाग / Dept.

पुलिस / P.O.  
फोन नं. 26588360, 26593444

पता / Address

रोगी / Patient Name

पता / Address

रोगी / Patient Name

पता / Address

रोगी / Patient Name

OPR-6

रोगी / O.P.D. Regn. No.

पता / Address

POC-78/20

रोग / Diagnosis

दिनांक / Date

31

उपचार / Treatment

Suspected B/L RB

MAI discussed in RC :

(12/13/20)

R orbit -> ON Intracranial

< 1cm (EORB)

L orbit -> Phthisis (+)

Brain (N)

DS ward  
L. D. Wajid

Phthisis

Memo

So  
R) EORB  
L) IORB gp E

CLEAN AND GREEN AIIMS / एम्स का यही संकल्प, स्वच्छता से काया कल्प

अंगदान-जीवन का बहुमूल्य उपहार / ORGAN DONATION - A GIFT OF LIFE

O.R.B.O., AIIMS, 26588360, 26593444, www.orbo.org Helpline - 1060 (24 hrs service)





अ० भा० आ० सं० अस्पताल / A.I.I.M.S. HOSPITAL  
बहिरंग रोगी विभाग / Out Patient Department  
अस्पताल के अन्दर धूमपान मना है / SMOKING IS PROHIBITED IN HOSPITAL PREMISES



OPR-6

एक/Unit  
विभाग/Dept  
नाम/Name

Follow Up Patient  
Dept Reg. 2020/001/0007144  
General/W O  
Paediatrics/Paediatric /Unit-122  
Name: सुष्मा कुमार  
Name: Mr. KRISHNA KUMAR  
Name: प्रियंका चौधरी  
170 JYANGRA CHAUDHARY  
Ph: 8089743310  
Date: 23/12/2020  
UMID: 105069674

No. \_\_\_\_\_  
पता/Address \_\_\_\_\_

निदान/Diagnosis

BLK RB  (R) CORB

दिनांक/Date

(4)

उपचार/Treatment

(4) OP BRB

13 Kg

Received 4 cycles of NACT

BMD Positive for metastatic disease  
metastatic disease

Post 3 cycles of chemo - MRI orbit + Brain =>

(NRe) => (Rt) eye mass present retrobulbar enhancing ON HLL optic canal, no Leptomeningeal enhancement  
non-operable

CSF - pleocytosis

plan to repeat MRI after 6 cycles

21/12/20

Hb-10.1  
PLT- 249 x 10<sup>3</sup>  
TLC- 5530  
ANC- 2470  
KES/LEP (2)

Next: Due for 5th cycle

- 1mg VCR 0.3 mg W (D1)
- 1mg CARBOPLATIN 360 mg W (D1)
- 1mg ETOPOSIDE 155 mg W (D1, P2)



CLEAN AND GREEN AIIMS / एम्स का यही संकल्प, स्वच्छता से काया कल्प  
अंगदान-जीवन का बहुमूल्य उपहार / ORGAN DONATION - A GIFT OF LIFE  
O.R.B.O., AIIMS, 26588360, 26593444, www.orbo.org Helpline - 1060 (24 hrs service)



### Staging

The IRSS is based on histopathology and imaging findings and takes into account that EORB with spread to regional LN has a rate of overall survival comparable to non metastatic EORB

### International Retinoblastoma Staging System (IRSS)

Stage	Description
Stage 0	Eye has not been enucleated and no dissemination of disease Conservative treatment
Stage I	Eye enucleated, completely resected histologically
Stage II	Eye enucleated, microscopic residual tumor in form of i. Tumor invasion into extrascleral space ii. Tumor invasion into cut end of ON
Stage III	Regional extension a. Overt orbital disease b. Preauricular or cervical lymph node extension
Stage IV	Metastatic disease a. Hematogenous metastasis (without CNS involvement) 1. Single lesion 2. Multiple lesions b. CNS extension (with or without any other site of regional or metastatic disease) 1. Prechiasmatic lesion 2. CNS mass 3. Leptomeningeal and CSF disease

### Metastatic workup (stage III & IV of IRSS)

Not indicated in stage 0 & 1 (stage II may need evaluation)

1. BM
2. LP for CSF examination
3. Bone scan

## Chemotherapy schedules

### standard chemotherapy protocol for RB

VCR	1.5 mg/m <sup>2</sup> /day/IV 0.05mg/kg/day for children < 3 yrs Max dose 2.0 mg	Day 1
Carboplatin	560 mg/m <sup>2</sup> /day 18.6 mg/kg/day for children <3 yrs	Day 1
Etoposide	150 mg/m <sup>2</sup> /day 5 mg/kg/day for children < 3 yrs	Day 1 & 2
Cycles every 3-4 wk Ensure ANC >1.0 & Platelet count >1,00,000/cumm LFT & RFT must be done before every cycle		

### NACT: CT followed by EN, local RT and adjuvant CT

VCR	0.025mg/kg/day Max dose 2.0 mg	Day 1
Carboplatin	28 mg/kg/day	Day 1
Etoposide	12 mg/kg/day	Day 1 & 2
Cycles every 3-4 wk Ensure ANC >1.0 & Platelet count >1,00,000/cumm LFT & RFT must be done before every cycle		

VCR	1.5 mg/m <sup>2</sup> /day/IV 0.05mg/kg/day for children < 3 yrs Max dose 2.0 mg	Day 1	Wk 0,6,12,18..
Carboplatin	560 mg/m <sup>2</sup> /day 18.6 mg/kg/day for children <3 yrs	Day 1 & 2	Wk 3,9,15,21..
Etoposide	100 mg/m <sup>2</sup> / 3.3 mg/kg/day for children < 3 yrs	Day 1,2,3	Wk 3,9, 15, 21
Cyclophosphamide	65mg/kg/day	Day 1	Wk 0.6,12,18..
Idarubicin/ Doxorubicin	10 mg/m <sup>2</sup> 30 mg/m <sup>2</sup> /day	Day 1	Wk 0.6,12,18..
Cycles every 3-4 wk Ensure ANC >1.0 & Platelet count >1,00,000/cumm LFT & RFT must be done before every cycle .ECHO at baseline/ as indicated			

## E. Indications for radiotherapy

### Plaque radiotherapy

Primary	Anterior large tumor < 8 mm in height
secondary	Tumors that fail to respond /recur with CT and other focal consolidative therapy

### EBRT

#### i. Intraocular tumor

(multifocal RB with diffuse vitreous seeds that fail to respond to CT)

#### ii. Microscopic residual disease (stage II & EORB stage III RB with 12 cycles of CT)

(Orbital RT & at sites of regional LN mets in stage IIIb RB)

#### iii. A young child with bilateral retinoblastoma who has active or recurrent disease after completion of chemotherapy and local therapies.

#### iv. Children with small tumors within the macula that do not respond to chemotherapy or have recurrent disease following chemotherapy

#### v. Stage IV disease (at sites of metastasis)

**F. Ophthalmic artery infusion of chemotherapy:** Direct delivery of chemotherapy into the eye via cannulation of the ophthalmic artery is a feasible and effective method for ocular salvage. Melphalan is the most commonly used chemotherapeutic agent.

ब० रो० वि० कार्ड  
O.P.D. Card



अनुभाग व दिन  
Section and Day VI  
बुधवार व शनिवार  
Wednesday & Saturday

कमरा नंबर  
Cabin No.

DR. RAJENDRA PRASAD CENTRE FOR OPHTHALMIC SCIENCES

Card No: 1050894  
Date: 30/09/2020  
Unit No: 070005 020370  
K. HISHNA J. JYKA 3YM  
S. CHITRA S. MAUDHARY  
Unit VI WED: 51  
Social No.: 32

MUMBAI, INDIA

इकाई का एकक  
Department's Unit

आयु  
Age

पता  
Address

दिनांक DATE	निदान DIAGNOSIS	उपचार Treatment
30-SEP-2020	R. Extracul RLB YE ? orange RB	
	* Please accomodate in Dharmykhala- Pt is under Treatment	
	Dr. R.P. Centre for Ophthalmic Sciences All India Institute of Medical Sciences New Delhi-110029	
	Recu MRI Recu Opri 3 cycles of NACT di opri (32) all of carb.	

कृपया इस कार्ड को सुरक्षित रखें तथा अस्पताल में दिखाने के समय हर वक़्त साथ लायें।  
Kindly keep this Card safely and bring it on your follow-up visits.

१. धूम्रपान निषेध २. कूड़ा कर्कट केवल कूड़ेदान में ही डालें ३. थूकिये नहीं



यु एच आई की संख्या  
UHID No.  
रोगी का नाम  
Name of the patient

Room No. 115

Address MUZAFFARPUR, BIHAR, INDIA  
Mobile: 8089743310



अ० भा० आ० सं० अस्पताल / A.I.I.M.S. HOSPITAL  
बहिरंग रोगी विभाग / Out Patient Department



अस्पताल के अन्दर धूम्रपान करना है। / SMOKING IS PROHIBITED IN HOSPITAL PREMISES

OPR-6

Follow up Patient  
Dept Reg. 2020/003/0007144  
General/W O  
Paediatric/Paediatric Unit-111  
Name: शुभा शुभा  
Name: Mr. KRISHNA KUMAR  
Age: 31 YR 2M 25D  
S/O: शिवम चौरा  
Ph. 8089743310  
Date: 11/11/2020  
UHID: 105089674

पंजीकृत सं./O.P.D. Regn. No. \_\_\_\_\_  
आयु / Age \_\_\_\_\_  
पता / Address \_\_\_\_\_

निदान/Diagnosis

दिनांक/Date

उपचार/Treatment

11/11/20  
Rw 50  
act chemo  
n 28/10  
30-9/11  
8.1) 6000 (1350)  
3000  
KFT - urea 39.8  
Creat 0.63  
LET-NR

1) To trace [CST reports] / BM report  
2) RC discussion of outside MRI.  
29/9, 31 Oct, ~~Nov~~  
3) To trace BM biopsy  
4) ~~Text~~ (As per RI Centre on 5/11/20  
3 more cycles of NAET  
before enucleation)  
& metastatic w.r.p.

epo R+ GORB- received.  
left GORB one cycle  
of chemo  
in March  
↓  
lost to FU.  
↓  
outside MRI done  
w/ 9/11/20 showed  
left cavernous  
sinus +  
Parasellar  
involvement  
left phthisical  
per outside  
report  
However RC  
discussion pending  
Received NAET  
on 5/10, 6/10  
& 27/10, 28/10.  
Rpt MRI done on 31/10.  
NRC - Rt - Mass in retrobulbar  
canal  
Cavernary on till optic  
chiasm  
No mass in Pined  
glau



CLEAN AND GREEN AIIMS / एम्स का यही संकल्प, स्वच्छता से काया कल्प  
अंगदान-जीवन का बहुमूल्य उपहार / ORGAN DONATION - A GIFT OF LIFE  
O.R.B.O., AIIMS, 26588360, 26593444, www.orbo.org Helpline - 1060 (24 hrs service)



No intraorbital involvement

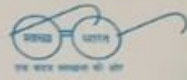डा० राजेन्द्र प्रसाद नेत्र  
अ० भा० आयु० सं०  
Dr. Rajendra Prasad Ch  
A.I.I.M.S., New Delhi-11  
यु एच आई सी संख्या  
UHID No.

रोगी का नाम  
Name of the patient

SCIENCE  
(DUPLICATE)  
ENID: 18889674  
Dept No. 20200050020370  
Clinic No.: 2020/RB/41  
KRISHNA KUMAR  
NO: JETAENDRA CHAUDHARY  
Date: 18/02/2020  
General  
Room No.: 115  
Address: MUZAFFARPUR, BIHAR, INDIA  
Mobile: 8089743310



अ० भा० आ० सं० अस्पताल / A.I.I.M.S. HOSPITAL  
बहिरंग रोगी विभाग / Out Patient Department  
SMOKING IS PROHIBITED IN HOSPITAL PREMISES



Follow up Patient  
Dept Reg: 2020/000/0007244  
General/P O  
Specialty/Consultant  
Name: कृष्णा कुमार  
Name: KRISHNA KUMAR  
Sex: किशोर पुरुष  
Sex: JETAENDRA CHAUDHARY  
PH: 8089743310  
UHID: 20200074 Date: 18/10/2020

OPR-6

रोगी सं०/पंजीकृत सं०/O.P.D. Regn. No. \_\_\_\_\_

लिंग Sex	आयु Age	पता/Address

निदान/Diagnosis

ClO Rt EORB -  
Left GP ERB. received and  
copy is  
March  
lost to HU

दिनांक/Date

उपचार/Treatment

11.00

MRI for diabetes 2  
To trace left & Bm reports  
Counseling for poor outcome  
to view of case involunt

MRI -  
Bm done  
- CSF, 9/10

MRI Brain  
outside shows

Left cavernous  
sinus left  
paracellar  
region.  
involunt.

left phthisic  
bulbi

Received  
HD VEC on 5/10/20  
6/10/20



CLEAN AND GREEN AIIMS / एम्स का यही संकल्प, स्वच्छता से काया कल्प  
अंगदान-जीवन का बहुमूल्य उपहार / ORGAN DONATION - A GIFT OF LIFE  
O.R.B.O., AIIMS, 26588360, 26593444, www.orbo.org Helpline - 1060 (24 hrs service)



089674

12

300 (6)

300 (6)


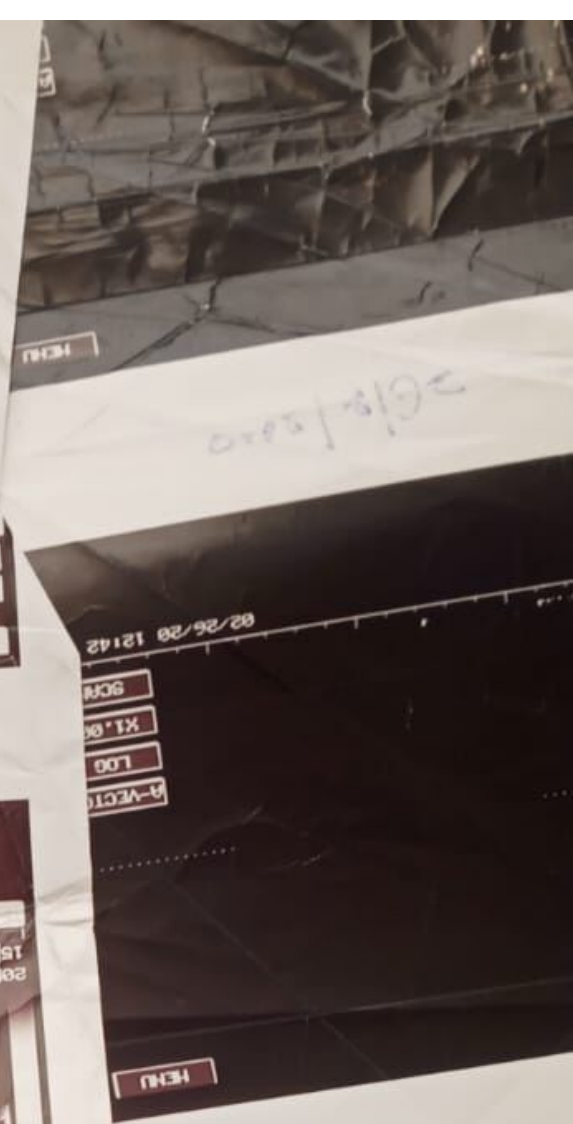

300 (6)

CL  
अंगदान  
O.R.B.O., AIMP

this card



60  
background noise





# DRISHTI EYE HOSPITAL & RESEARCH CENT

Sainikmode, Jhapa, Nepal  
Phone : 0097723545702 / 545703 / 545704  
Email: drishti.mechi@gmail.com

## OUT PATIENT CARD

Bill No.	CA0D0039272	MR No.		Unit	
Time	11:36:23 AM	Date	Feb 19, 2019 (FALGUN 07, 2075)		1 Yr 6 Mnth

Name : 182825 KRISHNA CHOUDHARY  
Address : MORANG

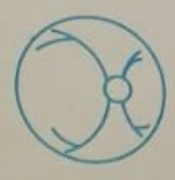
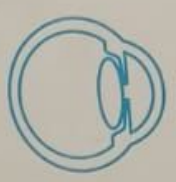
Age :  
Sex : Male

Visual Acuity < *poor bixab* With PH < With Glass <  
 Complain of : EYE : RE/LE/BE  
 Loss Diminution of VA : Sudden/Gradual *suspected* DVA : Near/Distance  
 Trauma/FB sensation *for RD* Eyeache/Headache/Giddiness  
 Fleshy growth  
 Duration : Redness/Discharge/Water  
 Itching/Irritation/Burning  
 Others: *no*

Systemic history : NS/DM/HTN/Asthma/Others : *Diabetes + open* Referred by :  
 Past: Medical History: H/O Surgery : RE/LE/BE for .....

Right Eye

Left Eye





Ph. 023-545566

# B & C Medical College

Teaching Hospital & Research Center Pvt. Ltd.  
Birtamode, Jhapa, Nepal

## DEPARTMENT OF ANAESTHESIOLOGY & CRITICAL CARE

### PRE-ANAESTHESIA ASSESSMENT RECORD

Date: 29/10/2025

Name: Krishna Chandary OPD/IP Registration No.: Weight:

Age/Sex | 55/110/M | Diagnosis Retinoblastoma Proposed Surgery: MRI

#### Short History

Chest pain : Y/N (NYSH I, II, III, IV)/ Breathlessness : Y/N (I, II, III, IV)/

Palpitation : Y/N; Syncope : Y/N ; Cough with expectoration : Y/N ; Asthma: Y/N: Allergies: Y/N

Jaundice : Y/N; Seizures : Y/N; Stroke: Alcohol: Y/N; Smoking Y/N

Family History:

Rashes all over body x 10-12 days  
w/o fever (+)

Medication

Previous Operation/Anaesthesia

Details of Medical Illness:

Beta mo - FND

#### Examination:

Nutrition : Pallor/Jaundice/Cyanosis/Neck Veins / Edema/ Thyroid/Peripheral Veins

Mouth Opening : Teeth / gums: Neck Movements :

Mallampatti : I/II/III/IV Tracheal position : Central / Deviated Spine:

### SYSTEMIC EXAMINATION

Respiratory System : B/L VBS (+)

Respiratory rate : Chest Movement : Auscultation:

Breath holding time: Matchstick test : PEFR :

Cardiovascular System: S1 + S2/mo

Heart rate : Rhythm: BP: Heart sound/Added sounds:

Hypertension: Recent/Old Controlled/Uncontrolled IHD

Congenital/valvular disorder:



## Treatment

### A. Consolidative therapy

Focal consolidative measures are used in early intraocular tumors (ICRB A-D) following chemoreduction (2-3 cycles) OR primarily and include

Laser photocoagulation	Posterior tumor , < 2mm in height
Cyotreatment	Peripheral , <3 mm in base diameter & 1.5 mm in height
Thermotherapy	< 3 mm in height, involving macula /disc
chemothermotherapy	Posteriorly located tumors, larger than 15 mm in base diameter

### B. Enucleation

#### Primary

**Unilateral retinoblastoma** present with advanced disease

**Bilateral disease** where enucleation may be indicated for the eye with the most advanced disease that does not respond to chemotherapy (rarely, enucleation is indicated for both eyes),

Active tumor is present in an eye with no vision

Glaucoma

Pseudohypopyon

Iris nodules

Tumor invasion into the anterior chamber

Tumor touching posterior surface of lens

Buphthalmos

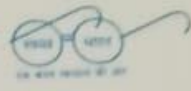Direct visualization of an active tumor is obstructed by conditions including vitreous hemorrhage, corneal opacity, or cataract .

Phthisis bulbi

Tapyloma



अ० भा० आ० सं० अस्पताल / A.I.I.M.S. HOSPITAL  
 बहिरंग रोगी विभाग / Out Patient Department  
 अस्पताल के अन्दर धूम्रपान मना है। / SMOKING IS PROHIBITED IN HOSPITAL PREMISES



OPR-6

एकक / Unit \_\_\_\_\_  
 विभाग / Dept \_\_\_\_\_  
 नाम / Name \_\_\_\_\_

Follow up Patient  
 Dept Reg. 2020/001/0007144      General / W/O  
 Paediatrics/Paediatric Unit-III      Ward/Room: 10  
 नाम: कृष्णा कुमारी      Days: Wed, Sat (शु, शनि)  
 Name: KRISHNA KUMAR      Queue No: PS  
 पिता: शिवशंकर चौधरी      3V 4H 6D सुप/म  
 S/O: SHIVSHANKAR CHAUDHARY      Ph. 8089743310  
 UID: 105089674      Date: 23/12/2020

No \_\_\_\_\_  
 पता / Address \_\_\_\_\_

8089743310

निदान / Diagnosis

B/L RB      (R) GORB

उपचार / Treatment  
 (L) OP. ERB

दिनांक / Date

(4)

13 kg

Received 4 cycles 3 NACT

BMD →  
 Positive for  
 metastatic disease

Post 3 cycles 3 chemo - MRI orbit + Brain ⇒

CSF - Acellular

(NRe) ⇒ (R) eye mass present retrobulbar  
 enhancing on all optic canal, no  
 Leptomeningeal enhancement  
 ||  
 non-operable

↓  
 plan to repeat MRI after 6 cycles

21/12/20

Hb-10.1  
 PLT- 219 x 10<sup>3</sup>  
 TLC- 5530  
 ANC- 2470  
 KES/Les (N)

Plan: Due for 5th cycle  
 • 1mg VCR 0.3 mg W (D1)  
 • 1mg CARBOPLATIN 360 mg W (D1)  
 • 1mg ETOPOSIDE 155 mg W (D1, P2)




CLEAN AND GREEN AIIMS / एम्स का यही संकल्प, स्वच्छता से काया कल्प  
 अंगदान-जीवन का बहुमूल्य उपहार / ORGAN DONATION - A GIFT OF LIFE  
 O.R.B.O., AIIMS, 26588360, 26593444, www.orbo.org Helpline - 1060 (24 hrs service)





# TREATMENT PROTOCOL FOR RETINOBLASTOMA

Name: Krishna M Father's name: Ganesh Kumar Age: 22/10  
 Sex: Male POC NO: 7820 family history: nil  
 Squint/white reflex/diminishes vision/red eye/watering of eyes/Proptosis  
 Others: nil  
 Unilateral/bilateral: BL RB  
 MT: nil HBsAg: nil HIV: nil



**Baseline workup/Investigations**

USG.....  
 .....  
 .....


EUA..... BL GP ⊕ - RT TOR 39,  
 .....  
 .....

Indirect Ophthalmoscopy  
 .....  
 .....

CT/MRI date & report  
 .....  
 .....

Review of imaging at radioconference : Yes/No  
(R) orbit - orbital calcification seen  
(L) orbit - orbital calcification seen

Hb..... TLC..... Platelet..... ANC.....  
 SGOT/SGPT/S.Bil/SAP.....  
 MT..... HBsAg..... HIV.....



TLC.....Platelet.....ANC.....  
 SGOT/SGPT/5.BII/SAP.....HBsAg.....HIV.....  
 MT.....

- S/P EMCSOT (S/2nd) unbl 500 x 2 days
- S/P SGTTRAD (S/W) 7 ml A/D
- RI x 1 month for 8th cycle (20/01/2021)
- breast MRI after 8th cycle 19  
mm
- 71085 collect bone marrow before start  
 - collect MRI from day case.

12 PM BM biopsy → infiltration by metastatic  
 tumor ⊕  
 - positive for chromogranin and  
 synaptophysin → NSRCT +  
 neuroendocrine differentiation

↓

Kindly check metastatic discussion &  
 before next chemotherapy

h  
mm

डॉ. जगदीश प्रसाद मीना  
 Dr. Jagdish Prasad Meena  
 सह-आचार्य / Associate Professor  
 पाल्सीय विभाग / Department of Paediatrics  
 110029

ब. रो. वि. कार्ड

दोबिट

अनुभाग व दिन

and Day VI  
शनिवार  
& Saturday

कमरा नंबर  
Cabin No.

1:5089074  
Dept. Regn: 20/005/0020370  
Name: DR. KRISHNA KUMAR  
110 JETAENORA CHAUDHARY, IV, 140  
PH: 8089743317  
MUDAYAPUR, DINAR, INDIA  
Date: 31/10/2020

202010310-41

डा० राजेंद्र  
Dr. Rajendra  
A.L.M.S  
यु एच अ  
UHID

नाम

पता  
Address

दिनांक  
DATE

निदान  
DIAGNOSIS

उपचार Treatment

R/E EORB  
L/E 2 Group E RB

Received 3 cycles of CT @ Last on 28/10/20.

31 OCT 2020

(115)

MAI from 4 orbit  
E Content elevated  
& fats Suppural.

Neur. report

Defi need's only  
to for metastases  
workup

कृपया इस कार्ड को सुरक्षित रखें तथा अस्पताल में दिवाली के समय हर वक्त साथ लायें।  
Kindly keep this Card safely and bring it on your follow-up visits.


१. धूम्रपान निषेध २. कूड़ा कर्कट केवल कूड़ेदान में ही डालें ३. थकिये नहीं

Wed/Sat (32)

दिनांक - Date

उपचार- Treatment

DOA  
 04/04/20  
 R.No 34A, 8:30am  
 h



Advice :

- NVZ Out
- flat-AC
- 10p. digitaly Prod.
- Poor glass Out
- (RE) USG - mass with calcification

- Phisical bulbi
- inferior squab
- cataractous lens
- (LE)

D: B/L Group E RB.

→ ref to ~~Hand's~~ ~~myology~~. Dr Loni Sir's opinion for starting systematic  
 Chemotherapy  
 Dr. Jagdish Mehta's ~~staging screening~~  
 Myom efd (2) xrd  
 (BE)

नेत्र ईश्वरीय सर्वश्रेष्ठ उपहार है जिनका मनुष्य जीवन में दान करना परमश्रेष्ठ है।  
 इनकी पूर्ण रक्षा कीजिए ताकि ये आपकी रक्षा कर सकें।  
 Eyes are God's most precious gift to man kind. Take full care of them  
 So that they can take care of you.

Room 10

Dr. Stanley G. Mehta

(34A)  
 for Embolus  
 (Close)

ब० रो० वि० कार्ड  
O.P.D. Card

डा० राजेन्द्र प्रसाद नेत्र विज्ञान केन्द्र,  
अ० भा० आयु० सं०, नई दिल्ली - ११००२९  
Dr. Rajendra Prasad Centre for Ophthalmic Sciences



नेत्र अस्पताल केवल ही  
को आप ही देख सकते हैं

अनुभाग व दिन  
Section and Day VI  
बुधवार व शनिवार  
Wednesday & Saturday

कमरा नंबर  
Cabin No.

ब० रो० वि० कार्ड

DR. RAJENDRA PRASAD CENTRE FOR OPHTHALMIC SCIENCES

UHIID: 108609674  
Dept. No.: 20200950020370  
KRISHNA KUMAR 2Y M  
S/O: RAJENDRA PRASAD  
Date: 07/03/2020  
RPC OPD-Dr. NEIWETE  
LONI  
Unit-VI WED, SAT  
Room No.: 32

Address: MUZAFFARPUR, BIHAR, INDIA  
Mobile: 9089743310



अनुभाग व दिन  
Section and Day VI  
बुधवार व शनिवार  
Wednesday & Saturday

कमरा नंबर  
Cabin No.

27/3/20

न का एकक  
Anderson's Unit

आयु  
Age  
पता  
Address

Krishna Kumar

M 2y

दिनांक  
DATE

निदान  
DIAGNOSIS

उपचार Treatment

27/02/2020

C/S/B NRC

neurovascular structures.

→ @ T2 heterogenous involving whole of  
rt globe. c some enhancement

Cannot rule out Rb or RD - inconclusive

Date for EUA  
next week.

07 MAR 2020

27/9/20 Kindly provide accommodation  
in Dhamra. (RB pt)

C/D/w  
Dr. N. Loni  
(CONSULTANT)

SR/UG  
RAC/AMMS

कृपया इस कार्ड को सुरक्षित रखें तथा अस्पताल में दिखाने के समय हर वक्त साथ लायें।  
Kindly keep this Card safely and bring it on your follow-up visits.

१. धूम्रपान निषेध २. कूड़ा कर्कट केवल कूड़ेदान में ही डालें ३. थूकिये नहीं

O.P.D. Card

द्र प्रसाद नेत्र विज्ञान केन्द्र,  
ब्रायु 0 सं०, नई दिल्ली - ११००००

अनुभाग व दिन  
Section and Day VI  
बुधवार व शनिवार  
Wednesday & Saturday

कमरा नंबर  
Cabin No.

अनुभाग व दिन  
Section and Day VI  
बुधवार व शनिवार  
Wednesday & Saturday

R.B - 41/20

व. र. के. ति. कार्ड

DR. RAJENDRA PRASAD CENTRE FOR OPHTHALMIC SCIENCES

CHID: 105089614  
Depd No. 20200050020370  
KRISHNA KUMAR IVN  
Dr. JITAENDRA CHAUDHARY

Date: 17/02/2020  
RPC OPD-De SR/IR  
UNDER-UNTIL-IV R.39A  
Cabin IV SIGN: JTD  
Room No. 39A

भाग व दिन  
Section and Day IV  
बुधवार व गुरुवार  
Wednesday & Thursday

कमरा नंबर  
Cabin No.

Address: MITRA NAGAR, BIHAR, INDIA  
Mobile: 2080-43510



एकक  
Unit

Name of the Patient

S/D/W

Sex

आयु  
Age

पता  
Address

दिनांक  
DATE

निदान  
DIAGNOSIS

उपचार Treatment

1/0 ~~red~~ whitish reflex x 3 months

HIO swelling in (L) → gradually became small.

AE (R) leucocoria

(L) pre phthical.

1 Anterior strom

(12/6) USC for AE PLE (R) moderate amplitude fibres in vitreous cavity S/O VU/VE ? RB  
fo H/O RB (L) small disorganised globe

कृपया इस कार्ड को सुरक्षित रखें तथा अस्पताल में दिखाने के समय हर वक्त साथ लायें।  
Kindly keep this Card safely and bring it on your follow-up visits.

- 1. धूम्रपान निषेध 2. कूड़ा कर्कट केवल कूड़ेदान में ही डालें 3. थूकिये नहीं

O.P.D. Card

द्र प्रसाद नेत्र विज्ञान केन्द्र,  
ब्रायु 0 सं 0, नई दिल्ली - 990000

अनुभाग व दिन  
Section and Day VI  
बुधवार व शनिवार  
Wednesday & Saturday

कमरा नंबर  
Cabin No.

अनुभाग व दिन  
Section and Day VI  
बुधवार व शनिवार  
Wednesday & Saturday

R.B - 41/20

व. र. के. ति. कार्ड

DR. RAJENDRA PRASAD CENTRE FOR OPHTHALMIC SCIENCES

CHID: 105089614  
Depd No. 20200050020370  
KRISHNA KUMAR IVN  
Dr. JITAENDRA CHAUDHARY

Date: 17/02/2020  
RPC OPD-De SR/IR  
UNDER-UNTIL-IV R.39A  
Cabin IV SIGN: JTD  
Room No. 39A

भाग व दिन  
Section and Day IV  
बुधवार व गुरुवार  
Wednesday & Thursday

कमरा नंबर  
Cabin No.

Address: MITRA NAGAR, BIHAR, INDIA  
Mobile: 2080-43510



एकक  
Unit

Name of the Patient

S/D/W

Sex

Age

पता  
Address

दिनांक  
DATE

निदान  
DIAGNOSIS

उपचार Treatment

1/0 ~~red~~ whitish reflex x 3 months

HIO swelling in (L) → gradually became small.

AE (R) leucocoria

(L) pre phthical.

1 Anterior strom

(12/6) USC for AE PLE (R) moderate amplitude spikes in vitreous cavity SLO VU/VE ? RB  
fo H/O RB (L) small disorganised globe

कृपया इस कार्ड को सुरक्षित रखें तथा अस्पताल में दिखाने के समय हर वक्त साथ लायें।  
Kindly keep this Card safely and bring it on your follow-up visits.

- 1. धूम्रपान निषेध 2. कूड़ा कर्कट केवल कूड़ेदान में ही डालें 3. थूकिये नहीं

ब० रो० वि० कार्ड  
O.P.D. Card



अनुभाग व दिन  
Section and Day VI कमरा नंबर

Section and Day VI  
बुधवार व शनिवार  
Wednesday & Saturday

कमरा नंबर  
Cabin No.

ब० रो० वि० कार्ड  
O.P.D. Card



अनुभाग व दिन  
Section and Day VI  
बुधवार व शनिवार  
Wednesday & Saturday

कमरा नंबर  
Cabin No.

डॉ० राजेन्द्र प्रसाद नेत्र विज्ञान केन्द्र,  
अ० भा० आयु० सं०, नई दिल्ली - ११००२९  
Dr. Rajendra Prasad Centre for Ophthalmic Sciences  
A.I.I.M.S., New Delhi-110029

वेदं अनुभव करो व  
जो आप को दे सकते हैं

यु एच आई डी संख्या  
UHID No. 105089674

आचार्य राधिका टंडन का एकक  
Prof. Radhika Tandon's Unit

रोगी का नाम Name of the patient	पुत्र/पुत्री/पत्नी S/D/W	लिंग Sex	आयु Age	पता Address
KRISHNA KUMAR		M	24	

दिनांक DATE	निदान DIAGNOSIS
----------------	--------------------

उपचार Treatment

19/2/20

QS/B Dr. Loni. in Ocular Oncology Clinic  
(Unit 6)

- Ⓡ RB on USA
- Ⓛ ptiasis bulbi

Advice →

- MRE Brain & orbit with Contrast enhanced, Fat Suppressed - Axial, Coronal, Sagittal sections with sections passing through optic nerve & pineal gland (2mm sections)

Urgent - CAN KIDS

- Date for EUA → for Staging → 21/2/20  
Come to 63<sup>rd</sup> SAM  
NPO from 2AM

कृपया इस कार्ड को सुरक्षित रखें तथा अस्पताल में दिखाने के समय हर वक्त साथ लायें।  
Kindly keep this Card safely and bring it on your follow-up visits.

१. धूम्रपान निषेध २. कूड़ा कर्कट केवल कूड़ेदान में ही डालें ३. धूकिये नहीं



ब० रो० वि० कार्ड  
O.P.D. Card

डा० राजेन्द्र प्रसाद नेत्र विज्ञान केन्द्र,  
अ० भा० आयु० सं०, नई दिल्ली - ११००२९  
Dr. Rajendra Prasad Centre for Ophthalmic Sciences  
A.I.I.M.S., New Delhi-110029



नेत्र अस्पताल का नारा है  
जहाँ अन्ध लोग भी देख सकते हैं

अनुभाग व दिन Section and Day	VI
बुधवार व शनिवार Wednesday & Saturday	

कमरा नंबर  
Cabin No.

यु एच आई डी संख्या

UHID No.

105089674

आचार्य राधिका टंडन का एकक  
Prof. Radhika Tandon's Unit

रोगी का नाम Name of the patient	पुत्र/पुत्री/पत्नी S/D/W	लिंग Sex	आयु Age	पता Address
Krishna Kumar		M	3y	Ph-8089743310

दिनांक DATE	निदान DIAGNOSIS	उपचार Treatment
	R/E Extraocular Retinoblastoma L/E ? Group E Retinoblastoma	

27/7/20

C/D/W Dr. Yogita (SR Unit VI).

Adv:

- Syp. Augmentin (228mg/5ml) 2.5ml TDS x 5 days
- Syp. PCM (250mg/5ml) 4ml BD x 3 days

RE { E/D HA 2/- BD  
E/D Iolien BD 10TIM BD  
E/D Oupol BD  
E/D Milfox BID

- Hygiene & cleaning explained, Dressing done.

कृपया इस कार्ड को सुरक्षित रखें तथा अस्पताल में दिखाने के समय हर वक्त साथ लायें।

Kindly keep this Card safely and bring it on your follow-up visits.

१. धूम्रपान निषेध २. कूड़ा कर्कट केवल कूड़ेदान में ही डालें ३. थूकिये नहीं



अ० भा० आ० सं० अस्पताल / **A.I.I.M.S. HOSPITAL**  
बहिरंग रोगी विभाग / **Out Patient Department**  
अस्पताल के अन्दर धूम्रपान मना है। / **SMOKING IS PROHIBITED IN HOSPITAL PREMISES**



OPR-6

एक/Unit  
विभाग/Dept  
नाम/Name

Follow Up Patient  
Dept Reg. 2020/001/0007144      General/W O  
Paediatrics/Paediatric Unit-111      Ward/Room: 10  
नाम: सुष्मा कुमारी      Days: Wed, Sat (सु. शनि)  
Name: Mr. KRISHNA KUMAR      Queue No.: F9  
पता: शिवमठ चौक      Jy 4th 60 पुणे, म  
1/0 JYAKNKA CHAUDHARY      Ph: 8089743310  
UMID: 105069674      Date: 23/12/2020

No. \_\_\_\_\_  
पता/Address \_\_\_\_\_

8089743310

निदान/Diagnosis

BLK RB      (R) CORB

दिनांक/Date

(4)

उपचार/Treatment

(L) OP BRB

13 Kg

Received 4 cycles of NACT

BMD Positive for metastatic disease  
metastatic disease

past 3 cycles of chemo - MRI orbit + Brain =>

(NRe) => (Rt) eye mass present retrobulbar enhancing on all optic canal, no leptomeningeal enhancement

CSF - pleocytosis

non-operable

21/12/20

plan to repeat MRI after 6 cycles

Hb-10.1  
PLT-249 x 10<sup>3</sup>  
TLC-5530  
ANC-2470  
KES/LEP (2)

Next: Due for 5th cycle

- 1mg VCR 0.3 mg W (D1)
- 1mg CARBOPLATIN 360 mg W (D1)
- 1mg ETOPOSIDE 155 mg W (D1, P2)



CLEAN AND GREEN AIIMS / एम्स का यही संकल्प, स्वच्छता से काया कल्प

अंगदान-जीवन का बहुमूल्य उपहार / ORGAN DONATION - A GIFT OF LIFE

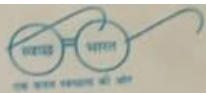O.R.B.O., AIIMS, 26588360, 26593444, www.orbo.org Helpline - 1060 (24 hrs service)



My Hospital  
meraaspatal.nhp.gov.in



अ० भा० आ० सं० अस्पताल / A.I.I.M.S. HOSPITAL  
बहिरंग रोगी विभाग / Out Patient Department



अस्पताल के अन्दर धूम्रपान मना है। / SMOKING IS PROHIBITED IN HOSPITAL PREMISES

OPR-6

New Patient  
Dent Reg. 2020/041/0007144  
GENERAL/78 0  
Date of Birth: 10/01/2014  
Name: KRISHNA KUMAR  
Age: 10  
Sex: M  
Address: 15/10, BHADRA CHAUDHARY JV BR 250 PURA/M  
Phone: 8089743330  
UNED: 101089674  
Date: 11/03/2020

ब० र० वि० पंजीकृत सं० / O.P.D. Regn. No.

लिंग Sex	आयु Age	पता / Address

निदान / Diagnosis

दिनांक / Date

15

उपचार / Treatment

Qo (L) eye small x 14s  
(R) eye whitish reflex - 4-32  
no fever  
no vomiting

(L) ear pain - on 20/2

ie - ACUTE  
systemic exam - normal

EUR (9/3/20) → (R) eye - group C RB  
(L) eye - group C RB + phthor

MR (orbit + brain) septa →  
(R) E → intra orbital mass seen in (R) eye globe,  
enhancement of proximal part of ON ⊕

(L) eye → phthor bulbi + intra orbital mass lesion ⊕



CLEAN AND GREEN AIIMS / एम्स का यही संकल्प, स्वच्छता से काया कल्प

अंगदान-जीवन का बहुमूल्य उपहार / ORGAN DONATION - A GIFT OF LIFE

O.R.B.O., AIIMS, 26588360, 26593444, www.orbo.org Helpline - 1060 (24 hrs service)





अ० भा० आ० सं० अस्पताल / A.I.I.M.S. HOSPITAL  
बहिरंग रोगी विभाग / Out Patient Department  
अस्पताल के अन्दर धूम्रपान मना है / SMOKING IS PROHIBITED IN HOSPITAL PREMISES



एकक/Unit

विभाग/Dept.

नाम/N

New Patient  
Inpt No. 2020/0089674  
General/P.O.  
Date of Birth: 19/01/2017  
Name of Patient: KRISHNA  
Sex: F  
Age: 3 yrs  
Address: 170, PUNE, M.  
Phone: 9089741110  
UPI: 105089674 Date: 03/03/2020

OPR-6

is/O.P.D. Regn. No.

पता/Address

105089674

निदान/Diagnosis

दिनांक/Date

उपचार/Treatment

Adv. → Please do early.

4116 Bh gentle ERM slr after instilling xylocaine.

Days Augmentin 2.5ml. X 7 days

Ciprox - D 2ld. X 7 days

lyc Calpol 2.5ml TDS. X 5 days.

RA 7 days

Bh ear discharge & pain recurrent x many months

Child. un-cooperative.

Bh EAC (cartilage) churning (+).

TM not an as kid is having pain.

TM attempted child very uncooperat

3/3/2020



CLEAN AND GREEN AIIMS / एम्स का यही संकल्प, स्वच्छता से काया कल्प  
अंगदान-जीवन की बहुमूल्य उपहार / ORGAN DONATION - A GIFT OF LIFE  
D.R.B.O., AIIMS, 26588360, 26593444, www.orbo.org Helpline - 1060 (24 hrs service)

My Hospital  
अस्पताल  
पथरी

...not forget to bring...  
...Toll Free no...  
...Please...  
...service...  
...5/5

MRB

- 2/10/20

उपचार



MRB ... Laser in Outer ...

Right Eye  
Past ...  
Sys ...

- (Unit 6)
- (R) RB on USA
- (L) pthisis bulbi

Advice ->

~~SR  
19/10/20~~

1. MRI Brain & orbit with contrast enhanced, Fat Suppressed - Axial, Coronal, Sagittal sections with sections passing through optic nerve & pineal gland (2mm sections)

Urgent - CAN KIDS

2. Date for EUA -> for Staging -> 21/2/20  
Come to 63 @ 8 AM  
NPO from 2 AM

कृपया इस कार्ड को सुरक्षित रखें तथा अस्पताल में दिखाने के समय हर वक्त साथ लायें।  
Kindly keep this Card safely and bring it on your follow-up visits.

१. धूम्रपान निषेध २. कूड़ा कर्कट केवल कूड़ेदान में ही डालें ३. थूकिये नहीं

CANKIDS...KIDSCAN  
CKID 105089674  
No. 25 Social Support Team

Eye Care System & RESEARCH CENTRE  
CLEAN AND GREEN AIIMS / अंगदान-जीवन का बहुमूल्य उपहार / ORGAN DONATION - A GIFT OF LIFE  
O.R.B.O., AIIMS, 26588360, 26593444, www.orbo.org Helpline - 1060 (24 hrs service)



Investigations :

IOP [ ] .....mm of Hg  
[ ] .....mm of Hg  
BP .....mm of Hg

ROPAS :

SYRINGING [ ]


EYE : RE

FEUM/Cycloplegic / Auto  
Orthoptics / Color Vision / Diplopia chart (S)  
Low vision / Contact Lens  
AVF / FDT / FFA / B-scan  
YAG Laser : YLC / PI  
Retinal laser : PRP / Grid / Sectoral  
Schirmer's Test / Gonioscopy  
Lab : Gram's / CBC / BT / CT / Platelet / Sugar : F / PP / R  
OTHERS :

Prcl  
→ calcification  
in retina  
→ PP  
S/O Retinoblastoma

REFRACTION :

P.G. : RE :  
LE :  
Add :



2 Retinoblastoma  
~~PAIR~~ → (2) ~~eyes~~  
microphthalmos

Diagnosis : OD / OS / OU :

RECOMMENDATION / PLAN :-

Refer to mechi EYE Hospital for management

BP KITHS DHARAMI

Drishiti

26 Feb 2019

Phone - Fax - Email

Krishna Chandra

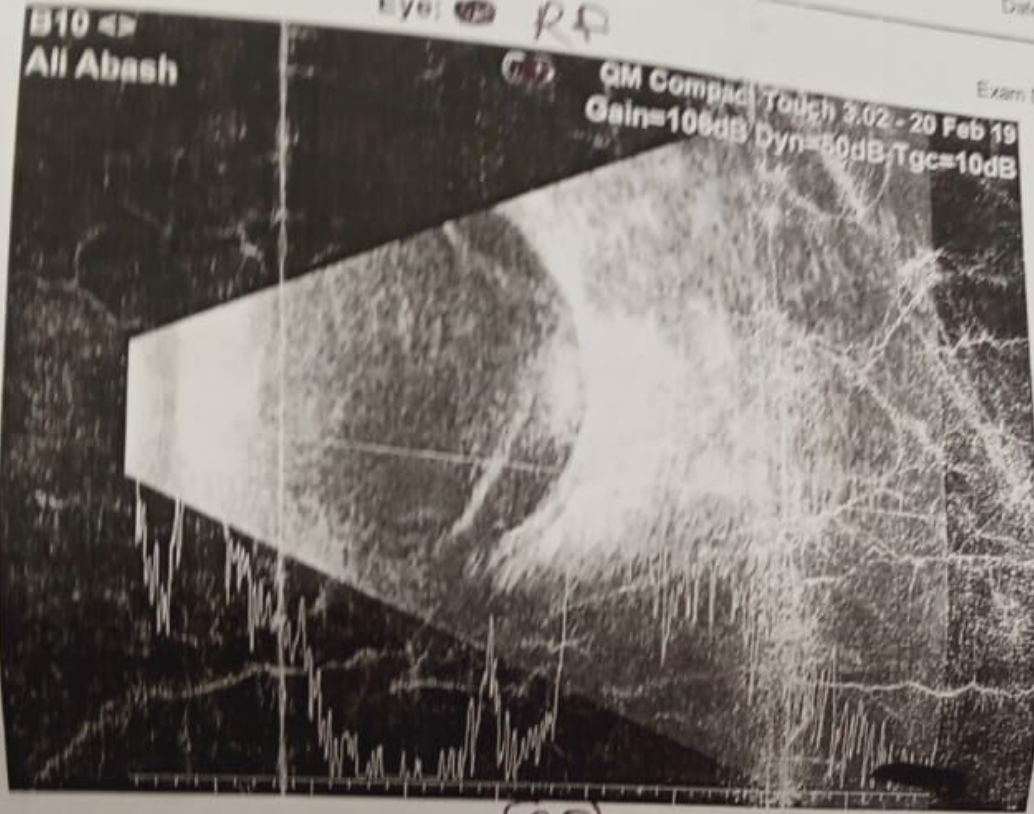
Gender

Id Number:

1828

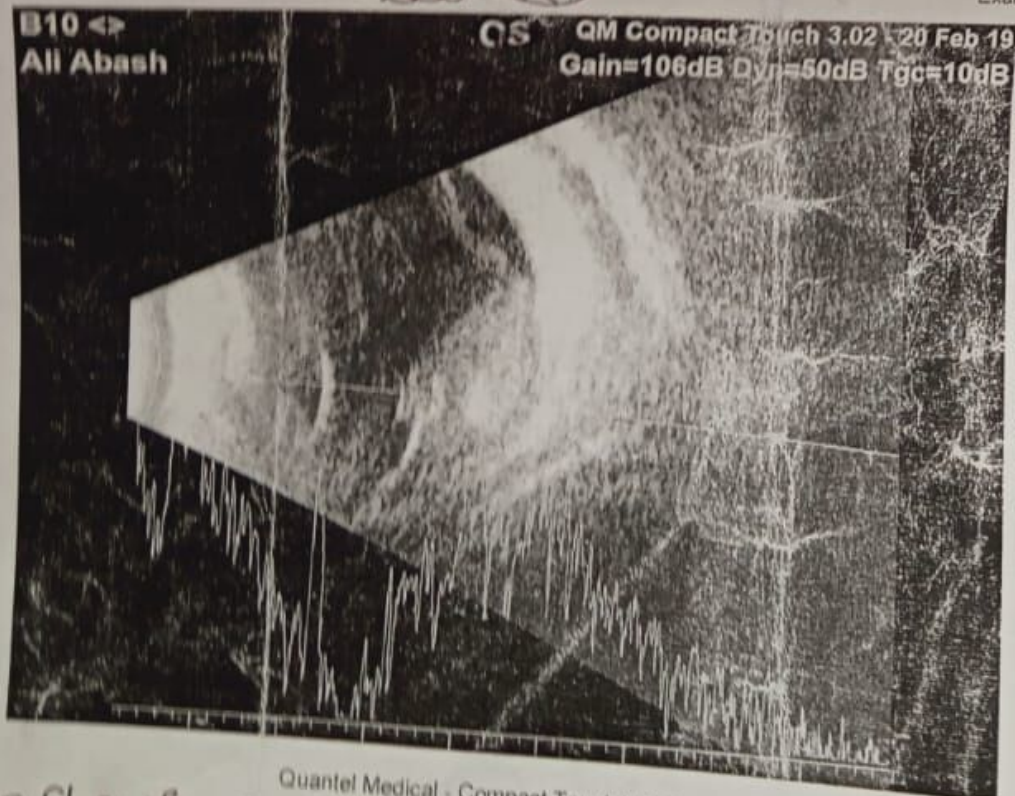
Date of birth: 01 Jan 1990

Exam Date: 20 Feb 2019



Eye: ~~OS~~ RF

Exam Date: 20 Feb 2019



Quantel Medical - Compact Touch V 3.02

scan shows

Deme vit abn

Next visit .....  
 Cycle no ..... Date 19/3/2020  
 Hb 10 TLC 6880 ANC 32% Platelets 3 L  
 SGOT 30 SGPT 13 S Bil 0.12 Urea 19 Creatinine 0.13

Drugs	Dose given	Day
VCR	0.3 mg iv slow push	D1
Carboplatin	336 mg / 200 ml NS iv 2 hr	D1
Etoposide	144 mg / 300 ml NS iv 3 hr	D1

Next visit.....

Cycle no ..... Date .....  
 Hb ..... TLC ..... ANC ..... Platelets .....  
 SGOT ..... SGPT ..... S Bil ..... Urea ..... Creatinine .....

Drugs	Dose given	Day
VCR		
Carboplatin		
Etoposide		



Next visit.....

Cycle no 10 Date 19-3-2020  
Hb 10 TLC 6880 ANC 32% Platelets 3.09 L  
SGOT 30 SGPT 13 S Bil 0.12 Urea 19.3 Creatinine 0.17

Drugs	Dose given	Day
VCR	0.3 mg iv slow pr	<u>D1</u>
Carboplatin	336 mg / 200 ml NS iv 1 hr	<u>D1</u>
Etoposide	144 mg / 300 ml NS iv 3 hr	<u>D1</u>
		<u>D2</u>

Next visit.....

Next visit.....

Cycle no ..... Date.....  
Hb..... TLC..... ANC..... Platelets.....  
SGOT..... SGPT..... S Bil..... Urea..... Creatinine.....

Drugs	Dose given	Day
VCR		
Carboplatin		
Etoposide		

Next visit.....

कृपया इस कार्ड को सुरक्षित रखें तथा अस्पताल  
Kindly keep this Card safely and  
कॉन्सल्टिंग डॉक्टर का कार्ड को सुरक्षित रखें

Defamite / Irregular  
cycles

KRISHNA

Cycle no ..... Date 25/11/20 + 26.11.20.  
Hb 8.1 TLC 6000 ANC ..... Platelets 13L  
SGOT ..... SGPT ..... S Bil ..... Urea ..... Creatinine .....

Drugs	Dose given	Day
VCR	0.3 mg iv	D <sub>1</sub> ✓
Carboplatin	340 mg / 100 ml NS	D <sub>1</sub> ✓
Etoposide	145 mg / 100 ml NS	D <sub>1</sub> , D <sub>2</sub> ✓
		NY Prakasham.

Next visit.....

Cycle no ..... Date 23/12/20.

Hb ..... TLC ..... ANC ..... Platelets .....  
SGOT ..... SGPT ..... S Bil ..... Urea ..... Creatinine .....

Drugs	Dose given	Day
VCR	0.3 mg iv	D <sub>1</sub> ✓
Carboplatin	360 mg / 100 ml NS	D <sub>1</sub> ✓
Etoposide	155 mg / 100 ml NS	D <sub>1</sub> , D <sub>2</sub> ✓
		23/12/20
		24/12/20

## Classification & staging

### Intraocular

Intraocular retinoblastoma is localized to the eye and may be confined to the retina or may extend to involve other structures such as the choroid, ciliary body, anterior chamber, and optic nerve head. Intraocular retinoblastoma does not extend beyond the eye into the tissues around the eye or to other parts of the body.  
(Intraocular disease (Enucleation is curative in >95% of patients with unilateral disease.)

### Extraocular

Extraocular (metastatic) retinoblastoma has extended beyond the eye. It may be confined to the tissues around the eye (orbital retinoblastoma), or it may have spread to the central nervous system, bone marrow, or lymph nodes (metastatic retinoblastoma).

## Classification of intraocular RB

### Reese-Ellsworth Classification for Intraocular Tumors

Reese and Ellsworth developed a classification system for intraocular retinoblastoma that has been shown to have prognostic significance for maintenance of sight and control of local disease at a time when surgery and external-beam radiation therapy (EBRT) were the primary treatment options.

Group I: very favorable for maintenance of sight

1. Solitary tumor, smaller than 4 disc diameters (DD), at or behind the equator.
2. Multiple tumors, none larger than 4 DD, all at or behind the equator.

Group II: favorable for maintenance of sight

1. Solitary tumor, 4 to 10 DD at or behind the equator.
2. Multiple tumors, 4 to 10 DD behind the equator.

Group III: possible for maintenance of sight

1. Any lesion anterior to the equator.
2. Solitary tumor, larger than 10 DD behind the equator.

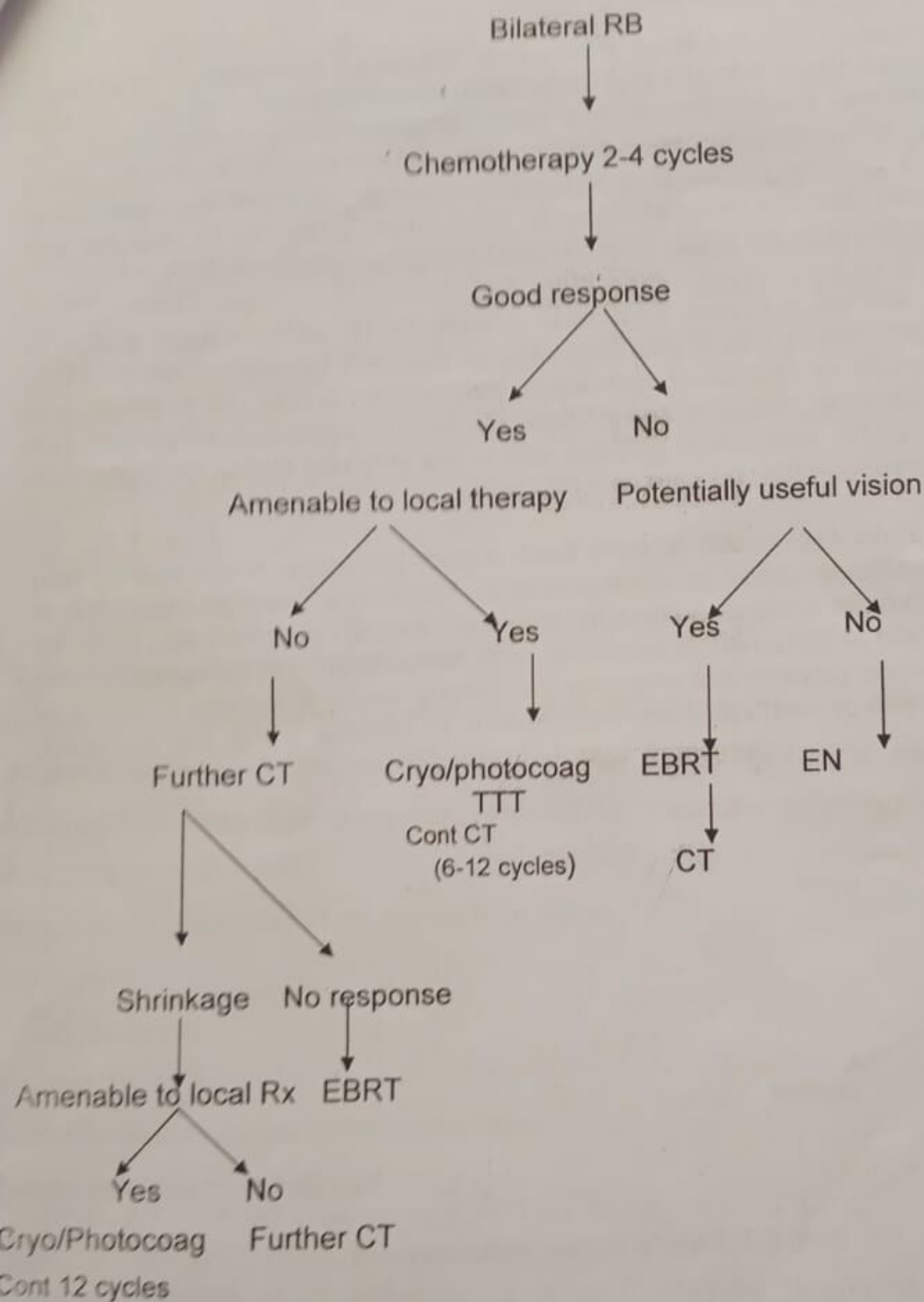
Group IV: unfavorable for maintenance of sight

1. Multiple tumors, some larger than 10 DD.
2. Any lesion extending anteriorly to the ora serrata.

Group V: very unfavorable for maintenance of sight

1. Massive tumors involving more than one half of the retina.
2. Vitreous seeding.

# Useful clinical approach to B/L RB



4



# अ० भा० आ० सं० अस्पताल / A.I.I.M.S. HOSPITAL बहिरंग रोगी विभाग / Out Patient Department



अस्पताल में जगह धूम्रपान तथा शि/SMOKING IS PROHIBITED IN HOSPITAL PREMISES

नाम / Name  
पता / Unit  
विभाग / Dept  
दिनांक / Date

पता / Address  
सं. / No.  
श. / Locality

OPR-6

दिनांक / O.P.D. Regn. No.

पता / Address

POC-78/20




### रोग / Diagnosis

दिनांक / Date  
31

उपचार / Treatment  
Suspected B/L RB  
MAI discussed in RC :  
(12/13/20)  
R orbit -> ON Intraorbital  
< 1cm (EORB)  
L orbit -> Phthisis (+)  
Brain (N)

DS ward  
L. D. Wajid

Phthisis



Memo



CLEAN AND GREEN AIIMS / एम्स का यही संकल्प, स्वच्छता से काया कल्प  
अंगदान-जीवन का बहुमूल्य उपहार / ORGAN DONATION - A GIFT OF LIFE  
O.R.B.O., AIIMS, 26588360, 26593444, www.orbo.org Helpline - 1060 (24 hrs service)





अ० भा० आ० सं० अस्पताल / **A.I.I.M.S. HOSPITAL**  
बहिरंग रोगी विभाग / **Out Patient Department**  
अस्पताल के अन्दर धूम्रपान मना है। / **SMOKING IS PROHIBITED IN HOSPITAL PREMISES**



OPR-6

एक/Unit  
विभाग/Dept  
नाम/Name

Follow Up Patient  
Dept Reg. 2020/001/0007144      General/W O  
Paediatrics/Paediatric Unit-111      Ward/Room: 10  
नाम: सुष्मा कुमारी      Days: Wed, Sat (सु. शनि)  
Name: Mr. KRISHNA KUMAR      Queue No.: P9  
पता: शिवमठ चौक      Jy 4th 60 पुण, न  
1/0 JYANGRA CHAUDHARY      Ph: 8089743310  
UMID: 105069674      Date: 23/12/2020

No. \_\_\_\_\_  
पता/Address \_\_\_\_\_

8089743310

निदान/Diagnosis

BLK RB      (R) CORB

दिनांक/Date

(4)

उपचार/Treatment

(L) OP BRB

13 Kg

Received 4 cycles of NACT

BMD Positive for metastatic disease  
metastatic disease

past 3 cycles of chemo - MRI orbit + Brain =>

CSF - Acellular

(NRe) => (Rt) eye mass present retrobulbar enhancing ON Hll optic canal, no Leptomeningeal enhancement  
non-operable

21/12/20

plan to repeat MRI after 6 cycles

Hb-10.1  
PLT- 249 x 10<sup>3</sup>  
TLC- 5530  
ANC- 2470  
KES/LEP (2)

Next: Due for 5th cycle  
• 1mg VCR 0.3 mg W (D1)  
• 1mg CARBOPLATIN 360 mg W (D1)  
• 1mg ETOPOSIDE 155 mg W (D1, P2)



CLEAN AND GREEN AIIMS / एम्स का यही संकल्प, स्वच्छता से काया कल्प  
अंगदान-जीवन का बहुमूल्य उपहार / ORGAN DONATION - A GIFT OF LIFE  
O.R.B.O., AIIMS, 26588360, 26593444, www.orbo.org Helpline - 1060 (24 hrs service)

